

Non-Compaction of the Ventricular Myocardium Associated with Aortic Aneurysm and Severe Aortic Insufficiency: Initial Description in Two Cases

Maryam Esmailzadeh MD, Maryam Moshkani Farahani MD, Firuzeh Abtahi MD, Mahmoud Momtahn MD, and Mohammad Bagher Tabatabaei MD

Abstract

Left ventricular hyper-trabeculation (LVHT), also known as left ventricular non-compaction (LVNC), is a rare myocardial abnormality of the apex and is characterized by multiple, myocardial cotyledon-like protrusions and interwoven strings, all lined by the endocardium. It may occur without any other cardiac abnormality (isolated LVNC) or may be associated with congenital cardiac malformations. In three quarters of cases, LVHT is associated with neuromuscular disorders. LVHT usually is congenital, but it was found to also develop later in life (acquired LVHT).

We report two cases of aortic aneurysm and severe aortic insufficiency with incidentally-diagnosed LVNC. To the best of our knowledge, there has been no previous report of LVNC associated with aortic aneurysm and/or aortic insufficiency (*Iranian Heart Journal 2009; 10 (2):40-44*).

Key words: left ventricle ■ myocardium ■ non-compaction ■ heart failure ■ aortic aneurysm ■ aortic insufficiency

Left ventricular hyper-trabeculation (LVHT), also known as non-compaction (LVNC), is a rare myocardial abnormality of the apex and is characterized by multiple, myocardial cotyledon-like protrusions and interwoven strings, all lined by the endocardium. It may occur without any other cardiac abnormality (isolated ventricular non-compaction) or may be associated with congenital cardiac malformations. In three quarters of cases, LVHT is associated with neuromuscular disorders.¹ Usually LVHT is congenital, but it was also found to develop later in life (acquired LVHT).^{2,3}

LVNC is echocardiographically defined as the presence of more than 3 coarse trabeculations apically to the papillary muscles, which have the same echogenicity as the myocardium, move synchronously with it, are not connected to the papillary muscles, and are

surrounded by intertrabecular spaces, which are perfused from the ventricular cavity.^{1, 2, 4, 5} LVNC may also be defined as numerous excessively prominent trabeculations and deep intertrabecular recesses, with a ratio of the non-compacted to the compacted layer >2. It may occur without any other cardiac abnormality (isolated ventricular non-compaction) or may be associated with congenital cardiac malformations, thickening of the left ventricular (LV) myocardium, cardiac emboli, atrial septal aneurysm, valve abnormalities, LV dilatation, decreased LV systolic function, or sudden cardiac death.⁷

Case reports

A 64-year-old man presented with dyspnea on exertion for several months' duration. On physical examination, there was bounding pulse, apical displacement of the PMI, LV

heave with decreased S₁ intensity, and a holodiastolic blowing murmur in the 3rd intercostal space.

Electrocardiogram showed LV hypertrophy with a severe LV volume overload pattern (Fig. 1).

Chest X-ray showed cardiomegaly with severe dilation of the ascending aorta.

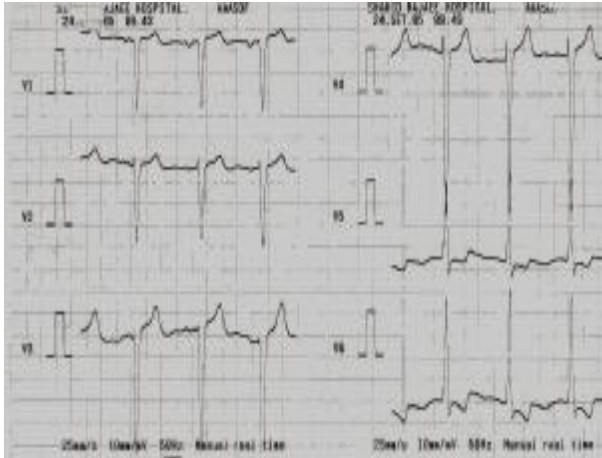
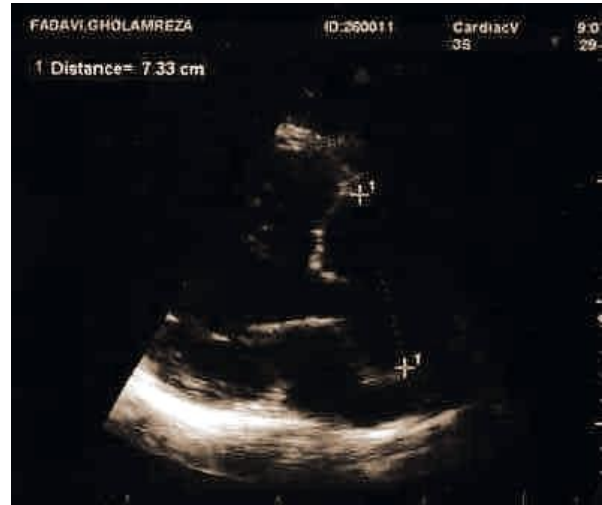

Fig. 1. ECG shows LVH with volume overload pattern in favor of severe AI.

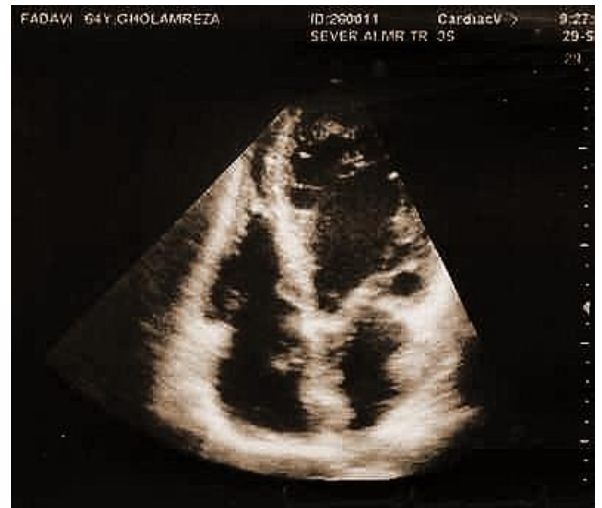On transthoracic echocardiography, there was severe aneurysmal dilation of the ascending aorta (9cm) with severe aortic regurgitation. The LV was highly trabeculated with deep intertrabecular recesses and non-compacted/compacted ratio=3 (Fig. 2).

The left ventricular ejection fraction was moderately reduced (LVEF=35%). Cardiac CT also showed the ascending aortic aneurysm, LV hyper-trabeculation, and coronary artery disease (Fig. 3).

The patient underwent coronary artery bypass grafting and Bentall procedure without any post-operative complication and was discharged from hospital after 2 weeks.



A



B

Fig. 2. Transthoracic parasternal long-axis view (A) and apical 4-chamber view (B) show ascending aortic aneurysm and hypertrabeculation of LV.

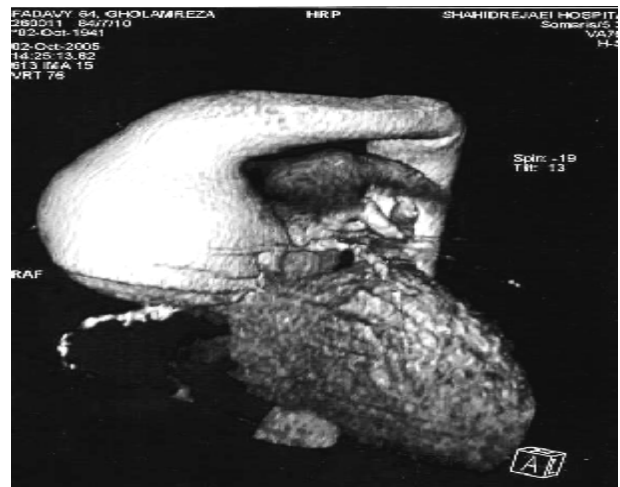


Fig. 3. Cardiac CT shows aneurysmal dilation of the ascending aorta with multiple trabeculations and deep intertrabecular recesses suggestive of LVNC.

Case 2

A 34-year-old man presented with a history of dyspnea on exertion from 3 months previously. On physical examination, he was a tall man with a height of 188cm. Vital signs were stable. His cardiac auscultation revealed a holodiastolic blowing murmur of aortic insufficiency.

Transthoracic echocardiography showed severe dilation of the ascending aorta (8.2cm) with severe aortic regurgitation. LVEF was moderately reduced, and the posterolateral segment of the LV showed heavy trabeculations with non-compacted/compacted ratio = 2. He was referred for surgery for a Bentall procedure.

Discussion

LVNC is a rare cardiac abnormality, echocardiographically defined as the presence of more than 3 coarse apical trabeculations to the papillary muscles, which have the same echogenicity as the myocardium and move synchronously with it, are not connected to the papillary muscles, and are surrounded by intertrabecular spaces, which are perfused from the ventricular cavity.^{1,2,4,5} LVNC may also be defined as numerous excessively prominent trabeculations and deep intertrabecular recesses, with a ratio of the non-compacted to the compacted layer >2. In addition to echocardiography, LVHT can be visualized by cardiac MRI and ventriculography.⁶ It may occur without any other cardiac abnormality (isolated LVNC) or may be associated with congenital cardiac malformations, thickening of the left ventricular myocardium, cardiac emboli, atrial septal aneurysm, valve abnormalities, LV dilatation, decreased LV systolic function, or sudden cardiac death.⁷

Congenital LVNC is assumed to be due to a disturbed endomyocardial compaction of the myocardium.²

Although occasional case reports have reported the association of mitral regurgitation and aortic stenosis with the echocardiographic features of non-

compaction^{8,9} there is no previous report of the association of aortic insufficiency and LVNC. Frischknecht et al. found non-compaction criteria in 0% of all patients with severe chronic aortic insufficiency in a large retrospective analysis which compared 19 patients with LVNC with randomly selected patients with dilated cardiomyopathy, hypertensive heart disease, chronic severe valvular disease including mitral and aortic regurgitation, and aortic stenosis.¹⁰ LVNC associated with mitral regurgitation has been previously reported;⁸ however, to our knowledge there is no previous report of LVNC associated with aortic insufficiency and ascending aortic aneurysm.

LVNC might be the result of an adaptation to special hemodynamic conditions. These theories are supported by the finding that a trabeculated myocardium has a markedly different viscoelastic behavior, influencing the rate and magnitude of contraction and relaxation, than the compact myocardium.¹¹ These theories are supported by the cardiac ventricle of the icefish, which is of spongy type with myocardial pseudohypertrophy. The ice fish heart functions as a specialized volume pump that moves large stroke volumes at a low heart rate, but is not able to produce high pressures.¹² Also in human beings, the right ventricle, which belongs to a low pressure system, is more trabeculated than the LV.¹ This pathophysiologic mechanism can explain the left ventricular hypertrabeculation in our two cases; both of them had chronic LV volume overload secondary to chronic aortic insufficiency.

Acquired LVNC may be explained as follows:

- 1) LVNC results from the dissection of the myocardium, impaired due to reduced adhesion of cardiomyocytes and malfunction of gap junctions.¹³ The myocardium is no longer able to merge with the endocardium, and blood burrows into the myocardium at a weak site, producing a widely branched cave which is steadily perfused by blood and thus endothelialized. That the apical region of the

LV myocardium, the lateral wall and the posterior wall are the predominant sites of LVNC may be due to the fact that these regions contribute most to the LV ejection force.¹³ Intraventricular pressure during systole in these regions is highest within the ventricle. Perforation of the myocardium is prevented because the subepicardial myocardial layers are more resistant to the ventricular pressure than the subendocardial layers.

2) LVNC results from a frustrated attempt to compensate for myocardial impairment by the underlying metabolic defect.³ After some time, the impaired myocardium is no longer able to develop contractility large enough to sufficiently eject blood from the LV. Accordingly, the myocardium starts to grow and its fibers become hypertrophic. However, this attempt has a low efficacy, given the inherited metabolic defect.

3) Exhaustion of the impaired myocardium causes the tearing up of the tissue due to dilatation. Myocardocytes are increasingly extended and tear if a certain limit of extension is exceeded.

4) Impairment of the myocardium leads to the hypervascularization of the subendocardial layer in the regions most in demand during systole. Sooner or later, the subendocardial vessels tear and the ventricular surface of the myocardium is transformed to a meshwork of interwoven myocardial strings.

5) Transformation of microinfarcts due to impaired oxidative metabolism or impaired microvascular supply, as in the brain, consequently leads to the transformation of the myocardium into LVNC.

6) Adaptation of the impaired myocardium occurs to move large stroke volumes at a low heart rate and low pressure. Which of these pathomechanisms or their combination are actually effective remains speculative.¹⁴

The pathophysiologic mechanisms of heart failure, systolic dysfunction, and arrhythmia in LVHT are not known. These are conditions that myocardial ischemia causes the observed abnormalities: hypoperfusion in the LVHT

areas could be demonstrated by Thallium-201 myocardial scintigraphy in 9 of 14 investigated patients with LVHT and in 1 further case using technetium 99m sestamibi imaging.^{15,16} A further study by positron emission tomography using M-13-ammonia in 5 children demonstrated restricted myocardial perfusion in LVHT areas.¹⁷ A further study in 12 patients using the same method showed that a decreased coronary reserve was not confined to segments with LVHT, but extended to most segments with wall motion abnormalities.¹⁸ In our older patient, i.e. case No 1, there was significant coronary artery disease needing coronary artery bypass grafting, which was diagnosed by CT angiography. Both chronic volume overload and coronary artery disease can explain the LVHT in this patient. In the second case, the patient refused any imaging technique for the evaluation of ischemia, but he also had the Marfan syndrome. It is not clearly defined whether LVHT, at least in our second case, is dependent either on chronic LV volume overload or on the cellular abnormality causing the progression of aortic aneurysm.

The evidence from these 2 cases indicates that LVNC can be associated with significant aortic insufficiency, as was in our cases secondary to ascending aortic aneurysm.

References

1. Stollberger C, Finsterer J. Left ventricular hypertrabeculation/non-compaction: Review Article. *J Am Soc Echocardiography* 2004; 17: 91-100.
2. Bleyl SB, Mumford BR, Brown-Harrison M-C, Pagotto LT, Carey JC, Pysher TJ, Ward K, Chin TK. Xq28-linked non-compaction of the left ventricular myocardium: Prenatal diagnosis and pathologic analysis of affected individuals. *Am J Med Genet* 1997; 72: 257-265.
3. Finsterer J, Stollberger C. Spontaneous left ventricular hypertrabeculation in dystrophin duplication based Becker's muscular dystrophy. *Herz* 2001; 26: 477-481.

4. Stollberger C, Finsterer J, Blazek G: Left ventricular hypertrabeculation/non-compaction and association with additional cardiac and neuromuscular disorders. *Am J Cardiol* 2002; 90: 899-902.
5. Chin TK, Perloff JK, Williams RG, Joe K, Muhrmann R. Isolated non-compaction of the left ventricular myocardium. A study of eight cases. *Circulation* 1990; 82: 507-513.
6. Finsterer J, Stollberger C, Wegmann R, Jarius C, Janssen B. Left ventricular hypertrabeculation in myotonic dystrophy type I. *Herz* 2001; 26: 287-290.
7. Dagdeviren B, Eren M, Oguz E. Non-compaction of ventricular myocardium, complete atrioventricular block and minor congenital heart abnormalities: Case report of an unusual coexistence. *Acta Cardiol* 2002; 17: 464-466.
8. Ali SKM, Omran AS, Najm H, Goldman MJ: Non-compaction of the ventricular myocardium associated with mitral regurgitation and preserved ventricular systolic function. *J Am Soc Echocardiography* 2004; 17: 87-90.
9. Sen Gupta PP, Mohan JC, Arora R. Non-compaction of left ventricular myocardium in the presence of calcific aortic stenosis in an adult. *Indian Heart J* 2001; 53: 766-8.
10. Frischknecht BS, Attanhofer Jost CH, Oechslin EN, et al. Validation of non-compaction criteria in dilated cardiomyopathy, and valvular and hypertensive heart disease. *J Am Soc Echocardiography* 2005; 18: 865-872.
11. Miller CE, Wong CL, Trabeculated embryonic myocardium shows rapid stress relaxation and non-quasilinear viscoelastic behavior. *J Biomech* 2000; 33: 615-22.
12. Agnisola C, Tota B. Structure and function of the fish cardiac ventricle: flexibility and limitations. *Cardioscience* 1994; 5: 145-53.
13. Bogaert J, Rademakers FE. Regional non-uniformity of normal adult human left ventricle. *Am J Physiol Heart Circ Physiol* 2001; 280: H610-H620.
14. Finsterer J, Stollberger C, Schubert B. Acquired left ventricular hypertrabeculation/non-compaction in mitochondriopathy. *Cardiology* 2004; 102: 228-230.
15. Ichida F, Hamamichi Y, Miyawaki T, Ono Y, Kamiya T, Akagi T, et al. Clinical features of isolated non-compaction of the ventricular myocardium: Long-term clinical course, hemodynamic properties, and genetic background. *J Am Coll Cardiol* 1999; 34: 233-40.
16. Elias J, Valadao W, Kuniyoshi R, Queiroz A, Peixoto CA. Miocardio nao compactado isolado. *Arq Bras Cardiol* 2000; 74: 253-7.
17. Junga G, Kneifel S, Von Smekal A, Steiner H, Bauersfeld U. Myocardial ischemia in children with isolated ventricular non-compaction. *Eur Heart J* 1999; 20: 910-6.
18. Jenni R, Wyss CA, Oechslin EN, Kaufmann PA. Isolated ventricular noncompaction is associated with coronary microcirculatory dysfunction. *J Am Coll Cardiol* 2002; 39: 450-4.