

# Aorta-to-Left Ventricle Tunnel Associated with Non-Compaction of the Left Ventricle

Mahdi Peighambari MD, Anita Sadeghpour MD, Mahboobeh Dalirrooyfard MD, Homayoon Zaheri MD and Mohammad Ali Yousefnia MD

## Abstract

We present a case of aorta-to-left ventricle tunnel and non-compaction of the left ventricle in a female of 26 years of age. She was referred to our echo lab for an evaluation of aortic regurgitation severity, and echocardiography revealed the diagnosis of the congenital abnormality of aorta-to-left ventricle tunnel and non-compaction of the left ventricle (*Iranian Heart Journal 2007; 8 (4): 60-62*).

**Key words:** non-compaction left ventricle ■ aorta-left ventricle tunnel

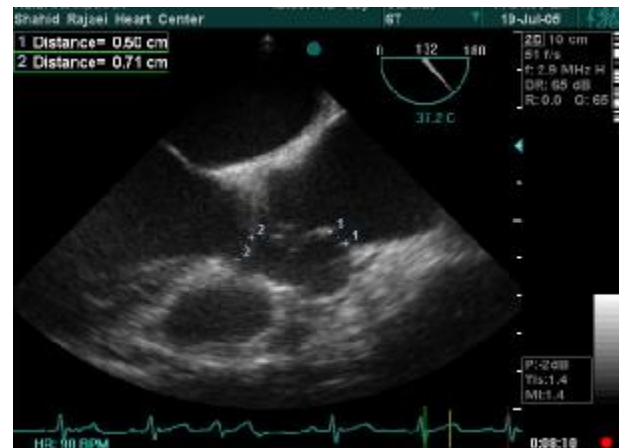**A**orta-to-left ventricle tunnel (ALVT) and left ventricular non-compaction (LVNC) are congenital heart diseases which define two distinct anatomic features. ALVT is a rare lesion in which a vascular connection between the aorta and the left ventricle exists.<sup>1</sup> LVNC is an unclassified cardiomyopathy characterized anatomically by deep trabeculations in the ventricular wall, which defines recesses communicating with the main ventricular chamber. We present a case of ALVT and LVNC presented to our clinic with a diagnosis of moderate to severe aortic valve regurgitation.

A 26-year-old female patient was referred to our clinic for an evaluation of the severity of aortic regurgitation. She had a history of dyspnea (functional class II).

In her medical history, she had a history of diastolic murmur and had been followed as aortic regurgitation for the previous 7 years. She could do her tasks well, but there was several months' history of increasing her functional class.

She had a to-and-fro murmur at her left sternal border on auscultation. Her electrocardiogram and chest X-ray showed no abnormality.

Transthoracic echocardiography (TTE) showed moderate left ventricular enlargement and an echo-free tunnel shape space from the ascending aorta to the left ventricle with flow going through it in systole and back to the left ventricle in diastole. Transesophageal echocardiography (TEE) demonstrated an echo-free space (35mm x 15mm) adjacent to the right and left coronary sinuses and above the level of the coronary arteries (Fig. 1).



**Fig. 1** Transesophageal echocardiogram showing echo-free space at commissure between the right and left aortic cusps

Received March 22, 2007; Accepted for publication July 5, 2007.

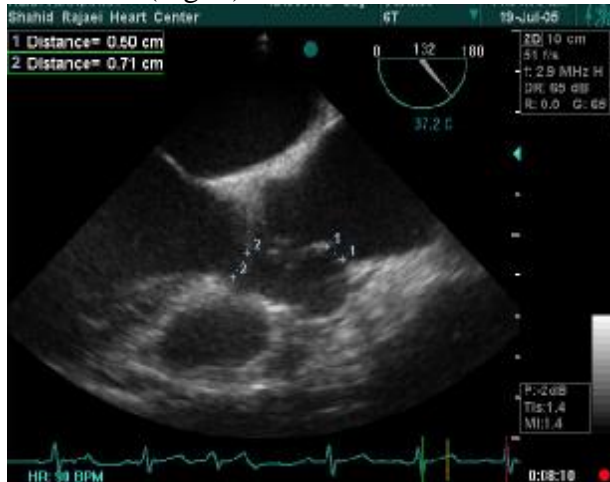
From the Department of Cardiology, Shaheed Rajaie Cardiovascular Medical Center, Iran University of Medical Sciences, Tehran, Iran.

Correspondence to: M. Peighambari MD, Shaheed Rajaie Cardiovascular Medical Center, Iran University of Medical Sciences, Tehran, Iran.

Tel: 0098-21-22070266, 0098-9123485611

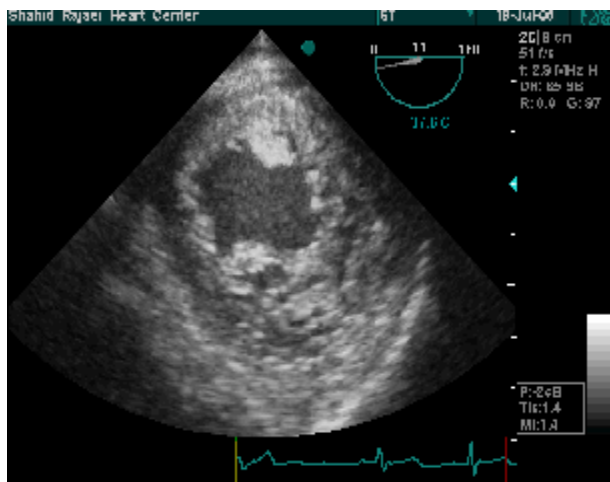
Fax: 0098-21-22295437

The aortic orifice diameter of the tunnel was 5 mm, and the left ventricle orifice diameter was 7 mm (Fig. 2).



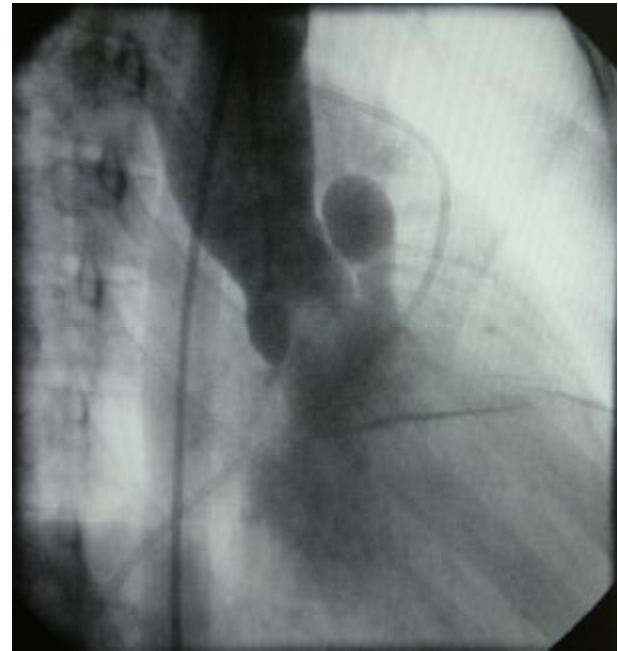
**Fig. 2.** Transesophageal long axis view showing aortic and left ventricular orifices

The aortic valve was tricuspid with mild regurgitation. Her ejection fraction was 50-55%. Pulmonary artery pressure was normal, and left ventricle study showed multiple trabeculations and recess formations and a non-compaction-to-compaction ratio exceeding 1.8/1, suggestive of LVNC (Fig. 3).



**Fig. 3.** Transgastric short axis view showing non-compaction of the left ventricle

Cardiac catheterization was done (Fig. 4), which confirmed the above data.



**Fig. 4.** Cardiac catheterization of aorta-to-left ventricle tunnel

She underwent cardiac surgery, and the diagnosis was confirmed by the surgeon. The tunnel was closed successfully, and she had an uneventful postoperative course.

## Discussion

ALVT is a congenital extracardiac channel which connects the ascending aorta above the sinotubular junction to the cavity of left or (less commonly) right ventricle. It begins in the anterior aspect of the ascending aorta above the level of the right coronary origin, and bypasses the aortic valve, behind the right ventricular infundibulum and through the anterior upper part of the ventricular septum to enter the left ventricle just inferior to the commissure between the right and left aortic cusps. It differs from a ruptured sinus of Valsalva aneurysm (sinus of Valsalva aneurysm fistula) in having its vascular orifice in the tubular aorta rather than a sinus of aortic valve.<sup>2</sup> Echocardiography is a well-established diagnostic procedure for showing the anatomy in congenital heart diseases. Cardiac catheterization is required only in cases with inadequate information about

coronary artery anatomy. Before surgical intervention for ALVT is undertaken, every effort should be made to diagnose the coronary artery anatomy, because failure to do so in the case of aberrant origin of a coronary artery may prevent successful surgical correction.<sup>5</sup>

LVNC results from intrauterine arrest in the normal process of myocardial compaction. A ratio of non-compacted to compacted myocardium of  $>2$  is diagnostic for non-compaction cardiomyopathy,<sup>3</sup> which has been reported with a high mortality rate. Many of them present as adults, some manifesting an "undulating" phenotype.<sup>4</sup>

We diagnosed the disease via TTE, and established the details through TEE. Transthoracic windows are usually adequate, as was the case in our patient; nevertheless, TEE may provide an alternate approach in patients with poor TTE windows. Afterwards, we performed angiography to rule out other coronary artery anomalies.

Treatment is surgical. Since ALVT is associated with congestive heart failure in infancy, in most cases surgical intervention is indicated in early childhood. Early operation is recommended to prevent the distortion of the aortic valve, dilatation of the left ventricle, and distortion of the aortic annulus. However, there is a high incidence of aortic incompetence after surgery. After some repairs, there may remain a mild to moderate aortic regurgitation that may result in aortic valve replacement. The operative risk is not low, but results are very encouraging.<sup>6</sup>

ALVT is a very rare congenital anomaly. LVNC or "spongy myocardium" is another rare congenital cardiomyopathy. Vijayalakshmi et al. reported the first case in which these two rare anomalies causing pump failure coexisted in a 4-year-old male and the tunnel was successfully treated non-surgically. Trans-catheter closure with the Amplatzer duct occluder was feasible and safe in their case.<sup>7</sup>

## Conclusion

When evaluating any patient with suspected aortic valvular incompetence, ALVT should be considered.

Echocardiography is the diagnostic investigation of choice. ALVT should be treated surgically as soon as possible in order to prevent any damage to the aortic valve and the left ventricle.

## References

1. Allen HD, Gutgesell HP, Clark EB, Driscoll DJ. Moss and Adams' Heart Disease in Infants, Children and Adolescents. 6<sup>th</sup> ed. Lippincott, William & Wilkins; 2001, pp. 685-686.
2. McKay R. Aorto-ventricular tunnel. *Orphanet* 2005 Mar; 1-5.
3. Oechslin EN, Attenhofer Jost CH, Rojas JR, et al. Long-term follow-up of 34 adults with isolated left ventricular non-compaction: a distinct cardiomyopathy with poor prognosis. *J Am Coll Cardiol* 2000; 36: 493-500.
4. Pignatelli RH, McMahon CJ, Dreyer WJ, Denfield SW, Price J, Belmont JW, et al. Clinical characterization of left ventricular non-compaction in children. *Circulation* 2003; 108: 2672-2678.
5. Van Son JA, Harnschi J, Schneider P, Mohr FW. Repair of aortico-right ventricular tunnel. *Eur J Cardiothorac Surg* 1998 Aug; 14 (2): 214-7.
6. Napoleone CP, Gargiulo G, Pierangeli A. Aortico-left ventricular tunnel: two new cases with a long-term follow-up. *Ital Heart J* 2001 Aug; 2(8): 624-6.
7. Vida VL, Bottio T, Stellin G. An unusual case of aorto-left ventricular tunnel. *Cardiol Young* 2004 Apr; 14(2): 203-5.