

# Evaluation of Right Ventricular Function after Coronary Artery Bypass Grafting

Z. Ojaghi MD, A. Moaref MD, F. Noohi MD, M. Maleki MD and A. Mohebbi MD

## Abstract

**Background-** Decreased right ventricular function is a suggested echocardiographic finding after coronary artery bypass grafting (CABG). However, the assessment of RV function is still technically difficult because of the complicated geometry of the RV. The significance and time course of RV dysfunction and its relation to left ventricular ejection fraction and pump time have not been elucidated, however.

**Objectives-** In this prospective study, we assessed RV function measured from echocardiographic tricuspid annular plane systolic excursion (TAPSE), myocardial systolic velocity and timing interval determined by Doppler tissue imaging (Sm), and myocardial performance index (tei index) obtained from cardiac time interval analysis.

**Methods-** In 30 patients accepted for CABG, a baseline echocardiography was done before operation, followed by repeated echocardiograms one week and one month after CABG. RV function was assessed using the magnitude of TAPSE, peak Sm measured at lateral tricuspid annulus and myocardial performance index defined as the sum of isovolumic contraction and relaxation time divided by ejection time. Also the time interval from the Q point of the electrocardiogram to the beginning of the tricuspid annular Sm and Em waves of tissue Doppler imaging was measured before and after operation.

**Results-** TAPSE and peak Sm velocity was significantly reduced one week after CABG (2.34 vs. 1.53 cm, 12.67 vs. 8.5 cm/s,  $p < 0.001$ ) and remained so after one month (1.65 cm, 8.9 cm/s). RV myocardial performance index (tei index) was significantly increased one week after CABG (0.35 vs. 0.78,  $p < 0.001$ ) and remained unchanged one month postoperatively (0.86). There was no significant difference in Q-S and Q-E intervals before and after CABG (89 vs. 92 ms, 433 vs. 411 ms).

**Conclusion-** RV function is significantly reduced after CABG and remained so after one month. The severity of RV dysfunction seems to be correlated with LVEF, duration of CPB time and extent of CAD (more severe postoperative RV dysfunction in patients with 3VD compared to 1VD or 2VD). There is no correlation between postoperative RV dysfunction and the number of grafts performed and RCA lesions (*Iranian Heart Journal 2007; 8 (1): 13-19*).

**Key words:** right ventricle ■ coronary artery bypass graft ■ dysfunction ■ echocardiography

---

The vulnerability of the right ventricle (RV) to ischemic injury during the period of cross clamping is becoming increasingly recognized.<sup>1</sup>

Decreased RV function has been proposed after CABG. The underlying mechanism leading to RV dysfunction is still unknown.

---

Received Sep 17, 2005; Accepted for publication Aug. 22, 2006.

From the Dept. of Echocardiography, Shaheed Rajaie Cardiovascular Medical Center, Mellat Park, Vali Asr Avenue, Tehran, Iran. Correspondence to: Z. Ojaghi, MD, Dept of Echocardiography, Shaheed Rajaie Cardiovascular Medical Center, Mellat Park, Vali Asr Avenue, Tehran, Iran.

Tel: (021) 23922494

Suggestive theories have been intraoperative ischemia, intraoperative myocardial damage, cardioplegia and pericardial disruption.<sup>2</sup> Furthermore it is not known if deterioration of RV function is related to the state of coronary artery perfusion.<sup>2</sup> Assessment of RV function is difficult owing to the complex structure and asymmetrical shape of the ventricle in contrast to the left ventricle, the right ventricular cavity does not resemble a clear three-dimensional geometrical solid to serve as a model for calculation. The EF calculated from radionuclide angiography is independent of a geometrical model and has become the standard method for determining right ventricular systolic function.<sup>3</sup> One of the currently used methods is measurement of the tricuspid annular motion (TAM) or tricuspid annular plane systolic excursion (TAPSE). This method is simple because it is devoid of complications, trabeculae and myocardial drop outs. In addition, the inter-observer and intra-observer variation in recording and calculating TAPSE is shown to be low.<sup>2,5,12</sup> It is able to discriminate patients with normal right ventricular function from those with abnormal function with good sensitivity and specificity compared to radionuclide ventriculography.<sup>2</sup>

Myocardial velocity determined by Doppler tissue imaging is a new technique that has been used recently to analyze right ventricular function.<sup>6-10</sup> Another recently proposed index used in this study is myocardial performance index (tei index), obtained from cardiac time interval analysis, defined as the sum of isovolumic contraction and relaxation time divided by ejection time.

This index allows noninvasive and quantitative estimation of global combined systolic and diastolic RV function without geometric evaluation.<sup>13,15,16</sup>

The present study evaluates TAPSE, tissue Doppler imaging, timing interval and tei index for assessing right ventricular function and change in RV function one week and one month after CABG.

## Methods

In all, 30 patients with a history of coronary artery disease were included prospectively in this study. Patients were accepted for CABG because of angina pectoris and significant coronary artery stenosis. Patients with history of recent myocardial infarction, atrial fibrillation, significant valvular heart disease, previous CABG and poor acoustic window were excluded. All patients underwent CABG with cardiopulmonary bypass and none of them had perioperative myocardial infarction. All patients were followed up for one month after CABG. All patients underwent echocardiographic examination (2D, Doppler and tissue Doppler imaging) before CABG, one week and one month after CABG (Table I).

**Table I. Basic characteristics of patients.**

Total cases	30
Age	53.6±9.2
Sex (male: female)	1:1
CAD type:	
1VD	2(6.7%)
2VD	7(23.3%)
3VD	21(70%)
RCA disease	25(83.3%)
LVEF:	25-60(mean:49.5%)
LVEF<50%	27%
LVEF≥50%	73%
Pump time	89.12±36.5min(36-157)
Grafted vessels:	
LAD	100%
LCX	73.4%
RCA	83.3%

## Echocardiography

Commercially available echocardiographic equipment was used (Vivid 3, GE) with tissue Doppler imaging capabilities. Recordings and calculations of different echocardiographic parameters were performed according to the recommendations of American Society of Echocardiography. Global left ventricular function was assessed using Simpson rule and visual estimation. 2D-guided M-mode recording of tricuspid annular motion toward the cardiac apex in systole at the RV free wall through the tricuspid annulus in the apical 4-

chamber view was recorded in such a way that the annulus moved along the M-mode cursor. The total systolic displacement was measured from end diastole (beginning of QRS complex at the ECG) to the highest point of contraction using the leading edge of the echoes; values equal to or more than 20 mm suggest normal RV systolic function.

Pulsed tissue Doppler imaging was performed by spectral pulsed Doppler signal filters, adjusting nyquist limit to 15-20cm/s (close to myocardial velocities) and using minimal optimal gain. In apical 4-chamber view, a 5 mm pulsed Doppler sample volume was placed at the RV free wall at the level of the tricuspid annulus. Pulsed tissue Doppler imaging is characterized by a myocardial systolic wave (Sm) and two diastolic waves: early (Em) and atrial (Am) (Fig. 1). Myocardial peak velocity of Sm was measured as an index of RV systolic function; values above 11 cm/s suggest normal RV systolic function. Also RV myocardial performance or tei index was calculated by tissue Doppler imaging as follows: (IVCT+IVRT)/ET. Values below 0.4 suggest normal combined systolic and diastolic function. Also Q-S and Q-E intervals (time interval between the Q point of the electrocardiogram to beginning of Sm and Em waves) were measured before and after operation.

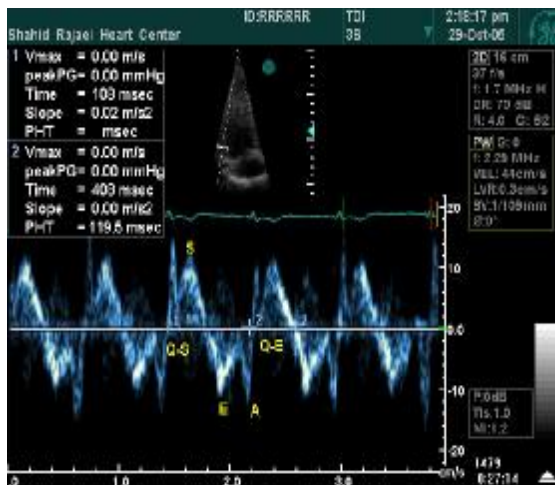


Fig. 1. Doppler imaging depicting systolic and diastolic waves.

### Statistical Analysis

For quantitative data, analysis of variance and t-test were used and for qualitative data, chi-square test was used. A p value less than 0.05 was considered significant.

### Results

Routine 2D echocardiographic and tissue Doppler imaging was performed for all 30 patients before operation, and one week and one month after operation.

Our main results showed that tricuspid annular motion or TAPSE was significantly reduced one week after operation and remained so one month postoperatively (P-value<0.001).

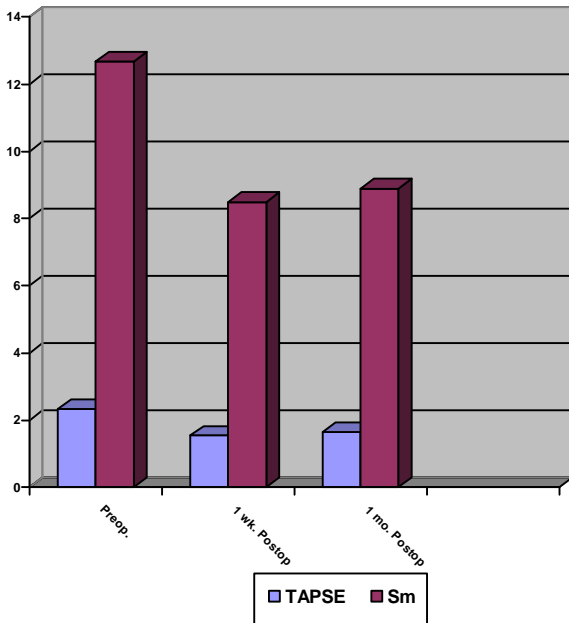
Also peak Sm velocity decreased significantly one week after operation, with no change at one month postoperatively (P-value<0.001, Fig. 2).

Myocardial performance index increased one week after operation with no change at one month (P-value<0.001, Fig. 3).

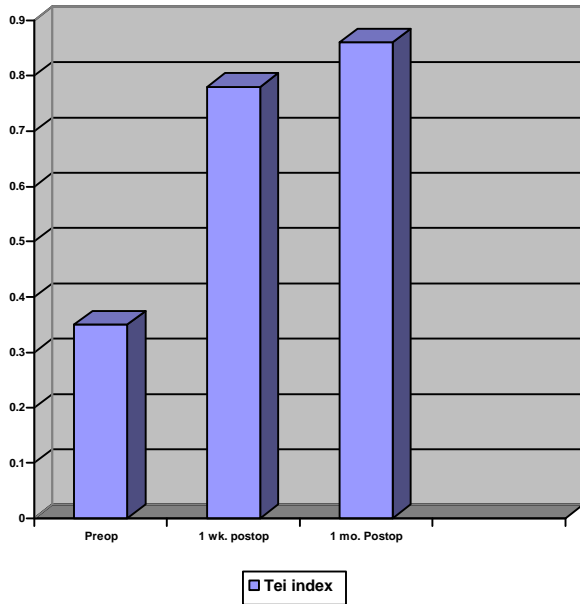
There was no significant change in Q-S and Q-E intervals before and after operation (Table II).

Table II. Changes in various indices measured before and after operation.

	Before operation	One week after operation	One month after operation
LVEF	49.5	45	45
TAPSE	2.34±0.36	1.53±0.34	1.65±0.29
Sm	12.67±2.6	8.5±1.7	8.9±1.5
Tei index	0.35±0.16	0.78±0.27	0.86±0.32
Q-S interval	89.10±26.1	92±30	102.36±28.6
Q-E interval	433.11±45.2	411.46±61.8	434±64.7



**Fig. 2.** RV function measured by Sm and TAPSE before and after operation.



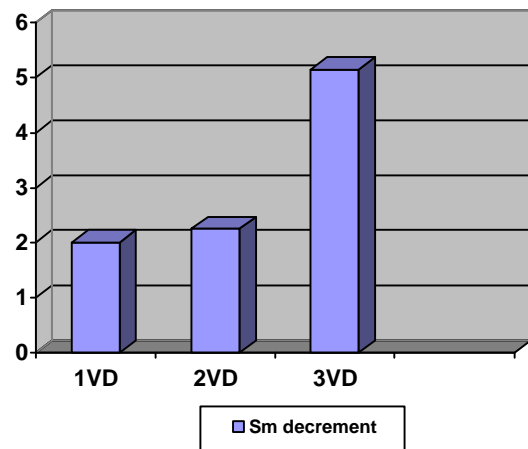
**Fig. 3.** RV myocardial performance index before and after operation.

LV dysfunction defined as LVEF less than 50% was seen in 27% of patients. There was no significant change in LVEF before and

after operation. Mean pump time in patients with LV dysfunction was 92.25min and in patients with normal LV systolic function (LVEF  $\geq$ 50%) 88.15 min, with no statistically significant difference (P-value=0.8).

There was an inverse relationship between LVEF and severity of RV dysfunction estimated by measurement of Sm velocity postoperatively (P-value <0.05, correlation: -0.122). Also there was significant direct relationship between severity of post-operative RV dysfunction and duration of cardiopulmonary bypass (CPB) time (P-value <0.05, correlation: 0.2).

There was no significant difference in tissue Doppler peak systolic velocity (Sm) of RV one week postoperatively between patients with single vessel disease and two vessel disease (mean decrease in peak Sm velocity is 2.0cm/s in 1VD and 2.25cm/s in 2VD, which is not significant, P-value: 0.7). But a significant difference in peak Sm velocity is seen in patients with 3VD compared to 1VD or 2VD (mean decrease in peak Sm velocity in patients with 3VD is 5.15cm/s which is significant, P-value < 0.05, Fig. 4).



**Fig. 4.** Decline in RV function measured by Sm decrement in patients with 1, 2 and 3VD.

Also, there was no significant correlation between severity of postoperative RV dysfunction and number of grafts that were used during CABG and whether RCA was grafted or not.

## Discussion

There is no gold standard for assessing RV function by echocardiography. This is partly due to the complex anatomy of the right ventricle. Right ventricular systole comprises a complex pattern of contractions of the RV myocardium along its long and short axes as well as rotation along its longitudinal axis.<sup>11</sup> As a result of RV contraction, the tricuspid annulus moves toward a stable apex during systole and returns toward the cardiac base during diastole. Using the amplitude of tricuspid annular motion from 1 or several sites, RV function has been described in healthy subjects and in patients with RV dysfunction. The magnitude of systolic tricuspid annular motion has been shown to be reduced in patients with RV infarction, atrial fibrillation, etc. Recording of the tricuspid annular motion is simple and feasible in most patients.

Assessment of myocardial function using myocardial velocity as assessed by TDI is new. The systolic and diastolic tricuspid annular velocities recorded by TDI represent the respective systolic and diastolic functions of the right ventricle and were found to be decreased in RV infarction, cardiomyopathy, etc.<sup>12,14</sup>

Right ventricular dysfunction after cardiac surgery is a well known phenomenon. RV dysfunction can be seen early after cardiac surgery. Both RV filling and RV contraction are impaired after CABG. The mechanism of this phenomenon is not well established. Although most studies included observation of RV function during and immediately after cardiac surgery, the long-term results of follow-ups of RV function are not fully known.<sup>17</sup> Few studies using the systolic tricuspid annular motion as a tool for evaluating RV function have reported a significantly reduced tricuspid annular motion immediately after CABG.<sup>17</sup> The reduced tricuspid annular motion recorded by M – mode echo was partly present 6 months after CABG.<sup>17-20</sup>

A previous study using pulsed wave TDI during dobutamine stress echocardiography showed a marginal increase in systolic tricuspid annular velocity after CABG. This finding might support the hypothesis that the reduced RV function after CABG can not be explained only by the development of stunning of the RV wall after CABG. In fact, there is no consensus about the exact mechanism of reduced RV function after CABG.<sup>2,17</sup>

After CABG, a preserved left ventricular function with a concomitant reduced RV function, might give rise to the question of an imbalance in flow from the right to the left side of the heart. The paradoxical movement of the interventricular septum, which was noticed in all the patients after CABG with cardiopulmonary bypass, might contribute to the retention of at least part of the RV function.<sup>17</sup>

## Conclusion

RV systolic function measured via TAPSE, Sm and tei index is significantly reduced one week after CABG and remains so one month postoperatively.

The severity of postoperative RV dysfunction correlates directly with the severity of preoperative LV dysfunction, i.e. more severe postoperative RV dysfunction is seen in patients with lower LVEF. Also patients with more prolonged pump time have more severe postoperative RV dysfunction.

No significant difference is seen in postoperative RV function between patients with 1VD and 2VD, but patients with 3VD have more severe postoperative RV dysfunction.

Also the number of grafts done during CABG or RCA grafting has no influence on postoperative RV dysfunction.

## Study Limitations

This study has some limitations. Only one site of the tricuspid annulus was studied. In

clinical practice, recording of other tricuspid annular sites might not be feasible in all patients. In addition, no exact method was included to assess the global RV function. In fact, there is no consensus regarding the echocardiographic assessment of global RV function. No invasive or radionuclide method for detecting RV function was used.

## References

- Mishra M, Swamintham M, Malhara M, Mishra A, and Trehan N. Evaluation of right ventricular function during CABG; transesophageal echocardiographic assessment of hepatic venous flow versus conventional right ventricular performance indices. *Echocardiography* 1998; 15: 51-8.
- Andres H, Mahbudul A, Zuber E, Nordlander R, and Samad BA. Decreased right ventricular function after coronary artery bypass grafting and its relation to exercise capacity. *J Am Soc Echocardiography* 2004; 17: 126-131.
- Ueti OM, Camargo EE, Ueti A, Lima-Filho EC, and Nogueira EA. Assessment of right ventricular function with Doppler echocardiographic indices derived from tricuspid annular motion. *Heart* 2002; 88: 244-249.
- Ghio S, Recusani F, Klersy C, Sebastiani R, Laudisa ML, Campana C, Gavazzi A, and Tavazzi L. Prognostic usefulness of the tricuspid annular plane systolic excursion in patients with congestive heart failure secondary to idiopathic or ischemic dilated cardiomyopathy. *Am J Cardiol* 2000; 85: 837-42.
- Hammarstrom E, Wrane B, Pinto FJ. Tricuspid annular motion. *J Am Soc Echocardiography* 1991; 4: 131-9.
- Meluzin J, Spiranova L, Bakala J, Toman J, Krejci J, Hude P, Kara T, and Soucek M. Pulsed Doppler tissue imaging of the velocity of tricuspid annular systolic motion. A new rapid and noninvasive method of evaluation of right ventricular systolic function. *Eur Heart J* 2001; 22: 340-8.
- Moustapha A, Lim M, Saika S. Interrogation of the tricuspid annulus by Doppler tissue imaging in patients with chronic pulmonary hypertension. Implication for the assessment of right ventricular systolic and diastolic function. *Cardiology* 2001; 95: 101-4.
- Ferlinz J, Gorlin R, Cohn PF, and Herman MV. Right ventricular performance in patients with coronary artery disease. *Circulation* 1975; 52: 608-15.
- Kaul S, Tei C, and Hopkins JM. Assessment of right ventricular function using two dimensional echocardiography. *Am Heart J* 1984; 107: 526-31
- Zoghbi WA, Habib GB, and Quinons MA. Doppler assessment of right ventricular filling in a normal population. Comparison with left ventricular filling dynamics. *Circulation* 1990; 82: 1316-24
- Oldershaw P. Assessment of right ventricular function and its role in clinical practice. *Br Heart J* 1992; 68: 12-5.
- Alam M, Wardell J, and Andersson E. Right ventricular function in patients with first inferior myocardial infarction: assessment by tricuspid annular motion and tricuspid annular velocity. *Am Heart J* 2000; 139: 710-5.
- Rafferty T, Durkin M, and Hines RL. Transesophageal two dimensional echocardiographic analysis of right ventricular systolic performance indices during coronary artery bypass grafting. *J Cardiothorac Vasc Anesth* 1993; 7: 160-166.
- Antonello D, Pio C, Sergio S, Berardo S, Alberto F, Gennaro C, Nicolino E, Marino S, Maurizio C, and Raffael C. Different involvement of right ventricular myocardial function in either physiologic or pathologic left ventricular hypertrophy: a Doppler tissue study. *J Am Soc Echocardiography* 2003; 16: 154-161.
- Won-Ho K, Yutaka O, Toshinori Y, Shinichi M, James B, and Chuwa Tei. Evaluation of right ventricular dysfunction in patients with cardiac amyloidosis using tei index. *J Am Soc Echocardiography* 2004; 17: 45-49.
- Tei C, Dujardin KS, and Hodge DO. Doppler echocardiographic index for assessment of global right ventricular function. *J Am Soc Echocardiography* 1996; 9: 838-47.
- Alam M, Hedman A, Nordlander A, and Samad B. Right ventricular function before and after an

- uncomplicated coronary artery bypass graft as assessed by pulsed wave Doppler tissue imaging of the tricuspid annulus. *Am Heart J* 2003; 146: 520-6.
18. Wranne B, Pinto FL, Hammarstram E, St Goar FG, Puryear J, and Popp RL. Abnormal right heart filling after cardiac surgery: time course and mechanism. *Br Heart J* 1991; 66: 435-42.
  19. Polak JF, Holman BL, and Wynne J. An indicator of increased mortality in patients with congestive heart failure associated with coronary artery disease. *J Am Coll Cardiol* 1983; 2: 217-24.
  20. Oakley C. Importance of right ventricular function in congestive heart failure. *Am J Cardiol* 1988; 62: 14-9A.