



# Noninvasive Localization of Accessory Pathways in Patients with Wolff-Parkinson-White Syndrome: A Strain Imaging Study

Maryam Esmailzadeh, MD, FACC, FCAPSC<sup>1</sup>, Mohammad Taghi Salehi Omran, MD<sup>2</sup>, Majid Maleki, MD, FACC, FCAPSC<sup>1\*</sup>, Majid Haghjoo, MD, FACC<sup>1</sup>, Feridoun Noohi, MD, FACC, FCAPSC<sup>1</sup>, Zahra Ojaghi Haghighi, MD, FACC<sup>1</sup>, Anita Sadeghpour, MD, FASE, FACC<sup>1</sup>, Paridokht Nakhostin Davari, MD<sup>1</sup>, Hooman Bakhshandeh Abkenar, MD<sup>1</sup>

<sup>1</sup>Echocardiography Research Center, Rajaie Cardiovascular, Medical and Research Center, Iran University of Medical Sciences, Tehran, Iran.

<sup>2</sup>Roohani Hospital, Babol University of Medical Sciences, Babol, Iran.

Received 25 March 2012; Accepted 15 July 2012

## Abstract

**Background:** Noninvasive techniques for the localization of the accessory pathways (APs) might help guide mapping procedures and ablation techniques. We sought to examine the diagnostic accuracy of strain imaging for the localization of the APs in Wolff-Parkinson-White syndrome.

**Methods:** We prospectively studied 25 patients (mean age =  $32 \pm 17$  years, 58.3% men) with evidence of pre-excitation on electrocardiography (ECG). Electromechanical interval was defined as the time difference between the onset of delta wave and the onset of regional myocardial contraction. Time differences between the onset of delta wave ( $\delta$ ) and the onset of regional myocardial contraction ( $\delta$ -So), peak systolic motion ( $\delta$ -Sm), regional strain ( $\delta$ - $\epsilon$ ), peak strain ( $\delta$ - $\epsilon$ p), and peak strain rate ( $\delta$ -SRp) were measured.

**Results:** There was a significant difference between time to onset of delta wave to onset of peak systolic motion (mean  $\pm$  SD) in the AP location (A) and normal segments (B) versus that in the normal volunteers (C) [A: ( $57.08 \pm 23.88$  msec) vs. B: ( $75.20 \pm 14.75$ ) vs. C: ( $72.90 \pm 11.16$ );  $p$  value (A vs. B) = 0.004 and  $p$  value (A vs. C) = 0.18] and [A: ( $49.17 \pm 35.79$ ) vs. B: ( $67.60 \pm 14.51$ ) vs. C: ( $67.40 \pm 6.06$  msec);  $p$  value (A vs. B) < 0.001 and  $p$  value (A vs. C) = 0.12, respectively].

**Conclusion:** Our study showed that strain imaging parameters [( $\delta$ -So) and ( $\delta$ -Strain)] are superior to the ECG in the localization of the APs (84% vs. 76%).

*J Teh Univ Heart Ctr 2013;8(2):65-69*

**This paper should be cited as:** Esmailzadeh M, Salehi Omran MT, Maleki M, Haghjoo M, Noohi F, Ojaghi Haghighi Z, Sadeghpour A, Nakhostin Davari P, Bakhshandeh Abkenar H. Noninvasive Localization of Accessory Pathways in Patients with Wolff-Parkinson-White Syndrome: A Strain Imaging Study. *J Teh Univ Heart Ctr 2013;8(2):65-69.*

**Keywords:** Accessory atrioventricular bundle • Wolff-Parkinson-White syndrome • Ablation • Diagnosis

\*Corresponding Author: **Majid Maleki**, Professor of Cardiology, Echocardiography Research Center, Rajaie Cardiovascular, Medical and Research Center, Iran University of Medical Sciences, Tehran, Iran. 1996911151. Tel: +98 21 2392192. Fax: +98 21 22055594. Email: majid33@yahoo.com.

## Introduction

Radiofrequency catheter ablation techniques have developed rapidly since 1990<sup>1, 2</sup> and have been deemed efficient therapy for the treatment of sustained supraventricular tachycardia and ventricular arrhythmias. Nevertheless, a reliable noninvasive approach for the localization of abnormal conduction and accessory pathways (APs) such as those in Wolff-Parkinson-White (WPW) syndrome has not been completely studied yet. Such a technique could be used to guide the radiofrequency ablation electrode to the proper cardiac chamber and target tissue and could help recognize the effectiveness of the ablation procedure. Currently, intracardiac electrophysiology and fluoroscopy are utilized to localize the site of abnormal ventricular stimulation, as is the case in the APs of WPW syndrome and ventricular arrhythmias. This time-consuming technique is, however, invasive and requires radiation exposure and does not provide spatial resolution of cardiac structures.<sup>3, 4</sup> Recently, it has been determined that tissue Doppler imaging (TDI) can display the distribution, direction, and amount of myocardial velocity and acceleration within the myocardium during the cardiac cycle.<sup>5-7</sup> The site of the initial contraction in WPW syndrome (or a ventricular arrhythmia) is recognized as the position of the initial velocity.<sup>8</sup>

In this study, we sought to examine the diagnostic accuracy of the noninvasive prediction of the AP localization in patients with WPW syndrome using strain imaging as a new noninvasive mapping procedure.

## Methods

The study was conducted from June 2010 to June 2011. Twenty-five patients (mean age =  $32 \pm 17$  years, 58.3% men) who had recurrent supraventricular tachycardia with the evidence of pre-excitation on electrocardiography (ECG) were prospectively studied. All the patients underwent electrophysiological endocardial mapping for the radiofrequency ablation of the suspected accessory bypass tract. A group of 25 healthy volunteers was investigated with echocardiography as the control group.

All the subjects were in sinus rhythm and had a normal left ventricular (LV) function under resting conditions. All the examinations and measurements were made by a single investigator, who was unaware of the electrocardiographic and electrophysiology study (EPS) data. Localization of the APs was defined with EPS as a gold standard.

Echocardiographic data acquisition was performed before the radiofrequency ablation of the APs. All the patients underwent color-coded tissue Doppler study using a Vivid 7 digital ultrasound scanner (GE, Milwaukee, Wisconsin, USA). Color-coded tissue Doppler cine loops from three

consecutive beats with optimal image quality were recorded. The images were obtained from the apical four-chamber, two-chamber, and apical long-axis views using a 3.5-MHz transducer at a depth of  $16 \pm 4$  cm. Gain was minimized to allow clear tissue signal with minimal background noise. Frame rate was more than 120/sec., and sweep speed was set at 100 mm/sec. The timing of the aortic valve opening and closure was determined from the pulsed-wave Doppler of the LV outflow tract and was superimposed on the tissue velocity and strain waveforms. All the measurements were performed in three representative cardiac cycles and averaged. The regions of interest were defined as a  $6 \times 6$ -mm area with a circular shape for tissue velocity measurements and as a  $6 \times 10$ -mm area with an oval shape for strain measurement, and they were placed in the basal and mid segments of the LV and right ventricular (RV) walls to measure the time interval from the onset of delta wave ( $\delta$ ) on the surface ECG to the time to onset and time to peak systolic velocity of TDI and time to peak systolic strain of strain imaging. All the intervals were corrected for heart rate (corrected interval = measured interval / [RR interval]<sup>1/2</sup>).

The patients were examined in the left lateral decubitus position with a conventional ultrasound system (VIVID 7) equipped with TDI, strain, and strain rate imaging. Apical four-chamber, two-chamber, long-axis, and RV inflow views were obtained: the apical four-chamber view to examine the RV lateral wall and the LV septal and lateral walls; the apical two-chamber view to examine the LV anterior and inferior walls; the apical long-axis view to examine the LV anteroseptal and posterior walls; and the RV inflow view to examine the RV posteroseptal and anterior walls.

The bipolar limb lead electrocardiogram (I, II, or III) that demonstrated the clearest onset of delta wave was selected and displayed on the ultrasound monitor.

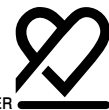All the recordings were set to measure the regional electromechanical delay. This electromechanical interval was defined as the time difference between the onset of electrocardiographic delta wave and the onset of regional myocardial contraction.

Localization of the APs was defined as the myocardial region with the shortest electromechanical time interval.

The following data were obtained (Figure 1): 1) time difference between the onset of delta wave ( $\delta$ ) and the onset of regional myocardial contraction ( $\delta$ -So); 2) time difference between the onset of delta wave and peak systolic motion ( $\delta$ -Sm); and 3) time difference between the onset of delta wave and onset of strain ( $\epsilon$ ), peak strain ( $\epsilon$ p), and peak strain rate (SRp).

Prediction of the localization of the APs from a standard twelve-lead ECG was made separately by an expert observer using three previously described algorithms.

The electrophysiologist who performed the endocardial mapping for the AP localization was blinded to echocardiographic data.



The site of successful radiofrequency ablation in one out of the five regions of left lateral (LL), left posteroseptal (LPS), right posteroseptal (RPS), right lateral (RL), and right anteroseptal (RAS) was used as the reference location for comparison with echocardiographic and electrocardiographic localization techniques.

The analysis of variance (ANOVA), the paired-sample t-test, and bivariate correlation tests were employed for inferential statistics. A normal distribution of the quantitative data was checked using the Kolmogorov-Smirnov test. The level of significance was set at 0.05.

### Results

APs were found in each of the 25 patients via invasive EPS. One patient was diagnosed as having atrioventricular nodal tachycardia. Successful radiofrequency catheter ablation was performed in all the patients.

Localization of the APs via the ECG and EPS and the frequency of the APs via EPS are depicted in Tables 1.

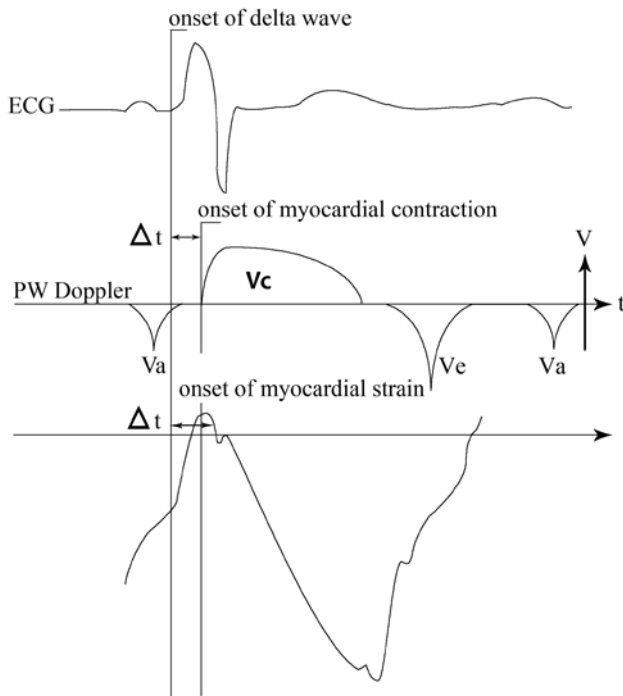


Figure 1. Time to onset of myocardial strain  
ECG, Electrocardiogram; PW Doppler, Pulse wave Doppler; V, Velocity; t, Time; Vc, Velocity of systolic contraction; Ve, Velocity of E wave; Va, Velocity of A wave; Δt, Time to onset of myocardial contraction

Statistical analysis was conducted with SPSS (Statistical Package for the Social Sciences version 15.0, SPSS Inc. Chicago, IL) software. The qualitative variables are expressed using percentages, while the quantitative data are defined using mean, standard deviation, and/or confidence intervals.

Table 1. Localization of the accessory pathways by electrocardiography and electrophysiology\*

AP location	ECG	EPS
Left lateral	10 (40)	12 (48)
Left posteroseptal	5 (20)	1 (4)
Right posteroseptal	8 (32)	8 (32)
Right anteroseptal	2 (8)	2 (8)
Right Lateral	0	2 (8)
Total	25 (100)	25 (100)

\*Data are presented as n (%)

AP, Accessory pathway; ECG, Electrocardiography; EPS, Electrophysiology study

Table 2 shows the frequency of the location of the APs using different TDI variables versus the ECG. The ECG had the highest positive predictive value (PPV) for the localization of the APs in the right RAS and LPS (100%), RPS (75%), and LL (83.3%). Time difference between the onset of delta wave and the onset of regional myocardial contraction ( $\delta$ -So) had the highest PPV for the localization of the APs in the LPS (100%) and LL (91.6%). The PPV of

Table 2. Frequency of accessory pathway localization using different tissue Doppler imaging variables versus electrocardiography\*

AP location	Number	$\delta$ -So	$\delta$ -Sm	$\delta$ -Strain	ECG
Left lateral	12	11 (91.6)	8 (66.6)	8 (66.6)	10 (83.3)
Right posteroseptal	8	-	-	8 (100)	6 (75.0)
Right anteroseptal	2	1 (50.0)	0	2 (100)	2 (100)
Right lateral	2	1 (50.0)	2 (100)	2 (100)	0
Left posteroseptal	1	1 (100)	1 (100)	1 (100)	1 (100)

\*Data are presented as n (%)

TDI, Tissue Doppler imaging; ECG, Electrocardiography; AP, Accessory pathway;  $\delta$ -So, Time difference between onset of delta wave and onset of regional myocardial contraction;  $\delta$ -Sm, Time difference between onset of delta wave and peak systolic motion;  $\delta$ -Strain, Time difference between onset of delta wave and onset of systolic strain

( $\delta$ - $\varepsilon$ ) for the localization of the APs in the LPS, RAS, RPS, and RL was 100%, as opposed to 66.6% in the LL.

There was a significant difference between the time to onset of delta wave to the onset of peak systolic motion (mean  $\pm$  SD) in the AP location (A) and normal segments (B) versus that in the normal volunteers (C) [A: (57.08  $\pm$  23.88 msec) vs. B: (75.20  $\pm$  14.75) vs. C: (72.90  $\pm$  11.16); p value<sub>(A vs. B)</sub> = 0.004 and p value<sub>(A vs. C)</sub> = 0.18] and [A: (49.17  $\pm$  35.79) vs. B: (67.60  $\pm$  14.51) vs. C: (67.40  $\pm$  6.06 msec); p value<sub>(A vs. B)</sub> = 0.000 and p value<sub>(A vs. C)</sub> = 0.12, respectively].

There was no significant difference in the strain and strain rate (mean  $\pm$  SD) of all the myocardial segments between the patients and the normal subjects [A: (-17.29  $\pm$  3.34%) vs. B: (-18.52  $\pm$  2.56%) vs. C: (-18.63  $\pm$  1.91); p value<sub>(A vs. B)</sub> = 0.57 and p value<sub>(A vs. C)</sub> = 0.22] and [A: (-1.33  $\pm$  0.33) vs. B: (-1.36  $\pm$  0.29) vs. C: (-1.45  $\pm$  0.48 s<sup>-1</sup>); p value<sub>(A vs. B)</sub> = 0.17 and p value<sub>(A vs. C)</sub> = 0.52, respectively].

There was a PPV of 100% for ( $\delta$ -Strain) for the localization of the APs in the LPS, RAS, RPS, and RL. The PPV of ( $\delta$ -Strain) for the localization of the APs in the LL was 66.6%. The highest PPV of ( $\delta$ -So) for the localization of the APs was seen in the LPS (100%) and LL (91.6%) and the lowest PPV of ( $\delta$ -So) for the localization of the APs was observed in the RL and RAS (50%) and RPS (0%).

In general, a PPV of 56% for TDI ( $\delta$ -So) and a PPV of 84% for strain imaging ( $\delta$ -Strain) were found for an accurate localization of the APs in the patients with WPW. Our study showed that strain imaging is superior to the ECG in the localization of the APs (84% vs. 76%). ( $\delta$ -Sm) had the lowest PPV for the detection of the location of the APs (44%).

## Discussion

M-mode echocardiography was the first modality to be employed for the localization of the APs in WPW syndrome and has been used since the mid-1970s.<sup>9</sup> However, because of its inherent limitation (unidimensional gray scale technique), the location of the ectopic excitation and pre-excitation induced by the APs could not be exactly defined.<sup>9</sup><sup>10</sup> The two-dimensional transthoracic and transesophageal echocardiographic phase analysis techniques have been drawn upon to localize the APs in WPW syndrome by evaluating the ventricular motion at early systole. Nonetheless, it is still difficult to localize an intramural focus of the earliest ventricular contraction. The phase angle in phase images presents the thickening of the ventricular wall and motion of the ventricular endocardium with lower temporal resolution (16 frames/s).<sup>11, 12</sup>

Some previous studies have revealed that even without the classic delta wave or wide QRS complex, tissue Doppler velocity imaging can localize the majority of the APs in WPW syndrome.<sup>8</sup>

The feasibility of TDI for evaluating the early contraction

sites in WPW syndrome was examined for the first time by Nakayama et al. in 1998.<sup>13</sup> They analyzed the time-sequential changes in ventricular wall motion in WPW syndrome with TDI, which demonstrated that the early contraction sites were well coincided with the sites of the APs, as determined by the electrophysiological examination (p value < 0.01). The authors suggested that TDI was helpful in localizing the APs and in evaluating the results after radiofrequency ablation.

In a study by Yin et al.<sup>14</sup> to validate the use of tissue Doppler acceleration imaging for the evaluation of the onset of ventricular contraction, the researchers concluded that this imaging modality was a useful noninvasive method that was successful in visualizing the intramural site of origin of ventricular mechanical contraction (agreement of 90% [18 of 20] for tissue Doppler acceleration imaging with the position of the APs localized from intracardiac electrophysiology testing). In another study by Tchnitz et al.<sup>15</sup> for a noninvasive prediction of the AP localization in patients with WPW syndrome using myocardial Doppler imaging, the investigators claimed that this imaging modality was superior to electrocardiographic algorithms for the localization of the AP (84% vs. 48-60%, respectively).

We found a lower PPV (56%) for the time difference between the onset of delta wave and the onset of regional myocardial contraction ( $\delta$ -So) in our patients.

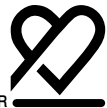In the article by Tada H et al.,<sup>16</sup> tissue tracking imaging was performed in 33 patients with idiopathic ventricular arrhythmias before radiofrequency catheter ablation. In that study, tissue tracking imaging provided detailed and accurate information on the arrhythmia origin, especially in the outflow tract, and facilitated the catheter ablation of idiopathic ventricular arrhythmias. Be that as it may, tissue tracking imaging cannot be considered as the modality of choice because of some limitations such as translational, rotational, and deformational movements. In addition, if the initial activation occurs in a plane perpendicular to the interrogating plane, tissue tracking may show tissue displacement from the adjacent areas due to tethering movements.<sup>17</sup>

Myocardial deformation, however, can be assessed from the B mode images by speckle tracking. It has the advantage of angle independence and may be superior to tissue Doppler-based techniques for strain estimation.<sup>17</sup>

The first report on the use of two-dimensional strain imaging technique to assess the origin of an accessory bypass tract in ventricular pre-excitation in a 51-year-old man with drug refractory WPW syndrome was published by De Boeck et al.<sup>18</sup> Using strain curves, the authors localized the site of the first ventricular contraction in the inferior wall, and invasive electrophysiological mapping confirmed a left-sided bypass with an inferoseptal ventricular insertion.

In some of our patients, it was difficult to define the precise beginning of delta wave. This problem may have altered





diagnostic accuracy. Doppler-based strain data are influenced by Doppler angle; nonetheless, particular attention was paid to make the segments as parallel to the ultrasonic beam as possible in our study. It is also deserving of note that only longitudinal strain and SR were measured in the present study. The accuracy of strain and SR would have been enhanced if circumferential, radial, and longitudinal strains had been measured simultaneously. A precise detection of the diagnostic yield of strain imaging for the noninvasive localization of the APs requires another study with a large sample size of all the known sites of the APs.

Our results suggest that strain imaging can be used to accurately predict single AP locations in patients with WPW syndrome. Strain imaging is a readily available and noninvasive procedure. Despite advanced mapping technology in the ablation procedures of WPW syndrome, there are still cases in which the exact localization of the right versus left lateral and right versus left posteroseptal pathways may be difficult.

Considering the different catheter approach in both of these localizations, TDI and strain data may provide important information for the electrophysiologist.

## Conclusion

TDI-derived parameters such as onset of systolic velocity ( $\delta$ -So) and strain ( $\delta$ -Strain) have better diagnostic yields than the ECG for the noninvasive localization of the APs in patients with WPW syndrome. Consequently, we would suggest that in some cases, the use of these parameters for a noninvasive prediction of the AP location may result in shorter invasive mapping durations and especially shorter X-ray exposure times.

## Acknowledgments

This study was approved and supported by Iran University of Medical Sciences.

## References

1. Klein LS, Shih HT, Hackett FK, Zipes DP, Miles WM. Radiofrequency catheter ablation of ventricular tachycardia in patients without structural heart disease. *Circulation* 1992;85:1666-1674.
2. Eldar M, Ohad DG, Goldberger JJ, Rotstein Z, Hsu S, Swanson DK, Greenspon AJ. Transcutaneous multielectrode basket catheter for endocardial mapping and ablation of ventricular tachycardia in the pig. *Circulation* 1997;96:2430-2437.
3. Blanchard SM, Walcott GP, Wharton JM, Ideker RE. Why is catheter ablation less successful than surgery for treating ventricular tachycardia that results from coronary artery disease? *Pacing Clin Electrophysiol* 1994;17:2315-2335.
4. Thakur RK, Guiraudon GM, Klein GJ, Yee R, Guiraudon CM.

- Intraoperative mapping is not necessary for VT surgery. *Pacing Clin Electrophysiol* 1994;17:2156-2162.
5. Sutherland GR, Stewart MJ, Groundstroem KW, Moran CM, Fleming A, Guell-Peris FJ, Riemersma RA, Fenn LN, Fox KA, McDicken WN. Color Doppler myocardial imaging: a new technique for the assessment of myocardial function. *J Am Soc Echocardiogr* 1994;7:441-458.
6. Miyatake K, Yamagishi M, Tanaka N, Uematsu M, Yamazaki N, Mine Y, Sano A, Hirama M. New method for evaluating left ventricular wall motion by color-coded tissue Doppler imaging: in vitro and in vivo studies. *J Am Coll Cardiol* 1995;25:717-724.
7. Caso P, Sutherland GR, Fleming A, McDicken WN. Doppler tissue imaging: current status and future prospects. *G Ital Cardiol* 1995;25:639-647.
8. Nakayama K, Miyatake K, Uematsu M, Tanaka N, Kamakura S, Nakatani S, Yamazaki N, Yamagishi M. Application of tissue Doppler imaging technique in evaluating early ventricular contraction associated with accessory atrioventricular pathways in Wolff-Parkinson-White syndrome. *Am Heart J* 1998;135:99-106.
9. DeMaria AN, Vera Z, Neumann A, Mason DT. Alterations in ventricular contraction pattern in the Wolff-Parkinson-White syndrome. Detection by echocardiography. *Circulation* 1976;53:249-257.
10. Lebovitz JA, Mandel WJ, Laks MM, Kraus R, Weinstein S. Relationship between the electrical (electrocardiographic) and mechanical (echocardiographic) events in Wolff-Parkinson-White syndrome. *Chest* 1977;71:463-469.
11. Kuecherer HF, Abbott JA, Botvinick EH, Scheinman ED, O'Connell JW, Scheinman MM, Foster E, Schiller NB. Two dimensional echocardiographic phase analysis. Its potential for noninvasive localization of accessory pathways in patients with Wolff-Parkinson-White syndrome. *Circulation* 1992;85:130-142.
12. Kuecherer HF, Kleber Gda S, Melichercik J, Schützendübel R, Beyer T, Brachmann J, Kübler W. Transesophageal echo phase imaging for localizing accessory pathways during adenosine-induced preexcitation in patients with the Wolff-Parkinson-White syndrome. *Am J Cardiol* 1996;77:64-71.
13. Nagai H, Takata S, Sakagami S, Furusho H, Takamura M, Yuasa T, Kobayashi K. Detection of the earliest ventricular contraction site in patients with Wolff-Parkinson-White syndrome using two-dimensional guided M-mode tissue Doppler echocardiography. *Cardiology* 1999;92:189-195.
14. Yin LX, Li CM, Fu GQ, Lo Y, Huang QH, Cai L, Zheng ZX. Ventricular excitation maps using tissue Doppler acceleration imaging: potential clinical application. *J Am Coll Cardiol* 1999;33:782-787.
15. Tchnitz A, Schmitt C, von Bibra H, Schneider MA, Plewan A, Schömig A. Noninvasive localization of accessory pathways in patients with Wolff-Parkinson-White syndrome with the use of myocardial Doppler imaging. *J Am Soc Echocardiogr* 1999;12:32-40.
16. Tada H, Toide H, Naito S, Ito S, Kurosaki K, Kobayashi Y, Miyaji K, Yamada M, Oshima S, Nogami A, Taniguchi K. Tissue tracking imaging as a new modality for identifying the origin of idiopathic ventricular arrhythmias. *Am J Cardiol* 2005;95:660-664.
17. Roy S, Sankar V, Francis J, Tada H. Tissue tracking imaging for identifying the origin of idiopathic ventricular arrhythmias: a new role of cardiac ultrasound in electrophysiology. *Indian Pacing Electrophysiol J* 2005;5:155-159.
18. De Boeck BW, Cramer MJ, Loh P, Doevendans PA. Images in cardiovascular medicine. Two-dimensional strain imaging to assess the origin and extent of ventricular preexcitation associated with an accessory bypass. *Circulation* 2006;113:e835-839.