

Behçet's Disease Presenting as Recurrent Right Ventricular Thrombus

Jalal Vahedian MD, FIAS, *Ali Sadeghpour Tabae MD,
**Hossein Azarnik MD and **Niloufar Samiei MD

Abstract

We report the case of a 17-year-old man with Behçet's disease, associated with a recurrent right heart thrombosis and pseudoaneurysm of the abdominal aorta. The patient was admitted to the surgical unit because of malaise, tachycardia, easy fatigability and fever.

The patient had a history of long standing low-grade fever, weight loss, fatigue, long-term headaches and non-specific skin lesions of the lower extremities. One month previously, an echocardiographic examination had revealed a right ventricular mass, thought to be a thrombus in an unusual location. The patient had consequently undergone surgery, and pathologic examination had confirmed the mass to be a thrombus.

When the patient was subsequently re-admitted to the emergency unit of our center with complaints of severe abdominal pain, fever, fatigue, sinus tachycardia and a pulsatile and tender abdominal mass, a right ventricular thrombus and a large pseudoaneurysm of the abdominal aorta were found on echocardiography and angiography, respectively. The patient underwent resection of the aortic aneurysm and aortoplasty and received immunosuppressive and anticoagulation therapy. The thrombus of the right ventricle disappeared 4 months later (*Iranian Heart Journal 2007; 8 (2): 51-55*).

Key words: Behçet's disease ■ cardiac thrombus ■ aortic pseudoaneurysm

Behçet's disease is a multi-systemic vasculitis of unknown etiology. In 1937, Hulusi Behçet, a dermatologist, first described the disease as a triad of oral and genital ulceration and ocular lesions. It is frequent among the Japanese and Mediterranean basin population. Vascular complications are a common component of this disease, but cardiac involvement is very rare. In such cases, known as cardio- Behçet's disease, reported symptoms include thrombus formation in the right atrium and right ventricle, tricuspid regurgitation, coronary

aneurysm and acute myocardial infarction due to coronary artery involvement.^{1,2}

We present a case with recurrent right ventricular thrombus and a large pseudoaneurysm of the abdominal aorta with impending rupture in a 17-year-old boy.

Case Report

A 17-year-old male patient was admitted to the emergency department suffering from malaise, tachycardia, fatigue, low-grade fever, weight loss and prolonged headaches.

Received Nov. 26, 2005; Accepted for publication Apr. 21, 2006.

From the Department of Surgery, Rassul-Akram Hospital and Research Center, Iran University of Medical Sciences and Health Services, Niayesh Street, Sattar-Khan Avenue, PO Box 1445613131, Tehran, Iran, * Department of Cardiovascular Surgery, and ** Department of Cardiology, Shaheed Rajaie Cardiovascular Medical and Research Center, Tehran, Iran

Corresponding author: J. Vahedian MD, Associate Professor of Surgery, Rassul-Akram Hospital and Research Center, Iran University of Medical Sciences and Health Services, Niayesh street, Sattar-Khan Avenue, PO Box 1445613131, Tehran, Iran Email: jahvahedian@yahoo.com

Remarkable past medical history was continuous headaches with intermittent exacerbation for the past year, managed as pseudotumor cerebri.

The patient had undergone cardiac surgery for a right ventricular mass one month previously (Fig. 1, A). A pathologic examination at the time had revealed an old and organized thrombus.

No lymphadenopathy was present. Non-specific papulo-pustular skin lesions were present in both legs. Chest exam and X-ray were normal. A physical examination of the abdomen revealed an emaciated young man with prominent eye globes and flexed knees toward his abdomen to reduce abdominal pain. A round and pulsatile mass about 15 cm in diameter was visible in the left supra-umbilical region, which was severely tender to palpation. The abdominal examination was otherwise normal. Distal pulses were normal.

Results of routine laboratory tests were normal except for moderate leukocytosis (WBC 11,300; neutrophil 78%, lymphocyte 15% and eosinophil 7%), high erythrocyte sedimentation rate (ESR 103mm/1st hr) and positive anti-phospholipid antibody. Computerized tomography angiography showed a bulging saccular pseudoaneurysm from the infra-renal aorta 15 cm in diameter parallel to the aorta with a connecting ostium to the aorta of about 1.5 cm in diameter (Fig. 2). While investigating the source of low-grade fever, we performed a transthoracic echocardiogram, which revealed a mass with solid and cystic nature in the right ventricle about 2.5 cm in diameter attached to the free wall. The fact that the mass was at the same site as the previous thrombus was suggestive of the recurrence of the thrombus (Fig. 1, B). Ejection fraction of the left heart was 30%; it was mildly reduced for the right heart. Patent foramen oval was also seen. A re-evaluation of the patient's past medical history revealed recurrent genital ulcers in addition to oral ulcer on one occasion. A diagnosis of Behçet's disease was made based on the criteria of the International Study Group for

Behçet's disease,³ consisting of oral and genital ulcers, papulo-pustular skin lesions, cardiac thrombus, cerebral involvement and prolonged and challenging headaches.

The pseudoaneurysm of the abdominal aorta was resected and aortoplasty was done. Anticoagulation with heparin was prescribed perioperatively. A treatment course of cyclosporine 150mg/day, prednisolone 30mg/day, colchicine 1mg/day and warfarin 5mg/day was added. The echocardiographic examination was repeated. The thrombus of the right ventricle disappeared 4 months after immunosuppressive therapy (Fig. 1, C). Ventilation perfusion scintigraphy was normal. Eight months after therapy, the patient was symptom free, and follow-up echo and sonography revealed normal findings.

Discussion

Hulusi Behçet, a dermatologist, in 1937 reported a triad of "oral ulcers, genital ulcers and relapsing uveitis" as the diagnostic criteria of Behçet's disease. This disease is now regarded as a systemic illness manifesting with recurrent oral or genital ulcers or large-vessel vasculitis, arthritis and meningoencephalitis.⁴ It is estimated that the rate of vascular involvement in Behçet's disease varies from 7-29%. Large arterial lesions are infrequent in Behçet's disease; they are estimated to occur in 1.5-2.2% of all patients with Behçet's disease.⁵ However, cardiac involvement is uncommon and occurs sporadically in Behçet's disease.⁶ Diffuse aortitis with resultant proximal aortic dilatation may lead to severe aortic regurgitation, requiring valve replacement.⁷ The prevalence of mitral and aortic valve prolapse is reported to be 6-50% in the literature.⁹ Other cardiac manifestations can include pericarditis, myocarditis, endocarditis^{6,10} and conduction system abnormality.^{9,10} Occasionally, coronary arterial involvement results in myocardial infarction.^{11,12} Cardiac thrombosis is a rare finding in Behçet's disease. Unfortunately,

there are few case reports about this unusual complication.^{4,13} Behçet's disease is a form of vasculitis syndrome characterized by inflammation of any size blood vessel wall.⁴ Intravascular thrombus formation in patients with Behçet's disease is attributed to endothelial cell injury from this vascular inflammation. Endothelial injuries leading to platelet aggregation, immune complexes causing impairment in fibrinolysis and decrease in the release of tissue plasminogen activator are the possible mechanisms in the pathogenesis of intravascular thrombus formation in vasculitis.^{14,15} Another explanation for thrombus formation in patients with Behçet's disease is the presence of anti-phospholipid antibodies, found in 18% of patients.¹⁶ Our patient had positive anti-phospholipid antibody. This antibody was reported previously in one patient with Behçet's disease and intracardiac thrombi.⁴ Anti-endothelial cell antibodies have been associated with vascular involvement.¹⁷ Nevertheless, there is no published evidence specific to intracardiac thrombosis. It is not known whether the anti-endothelial cell antibodies are also directed against antigens presented by the endocardial cell.⁴ It is recognized that organ involvement in Behçet's disease varies geographically, for instance GI involvement is common in Japan but rare in Turkey.¹⁹ Mogulkoc in a systematic review found only one case complicated by intracardiac thrombus among Far Eastern patients.¹⁹ This is consistent with the geographic variability in a model of clinical presentation and systemic organ involvement, suggesting that genetic predisposition may be highly relevant in determining systemic organ involvement in the disease. In conclusion, this case has demonstrated that Behçet's disease should be considered in terms of the heart and vessels, especially in the presence of right heart thrombus and/or bizarre involvement of the vascular tree. In such situations, heart thrombi can be treated medically.

Acknowledgments

We wish to thank Farshad Amouzadeh for editing the manuscript.

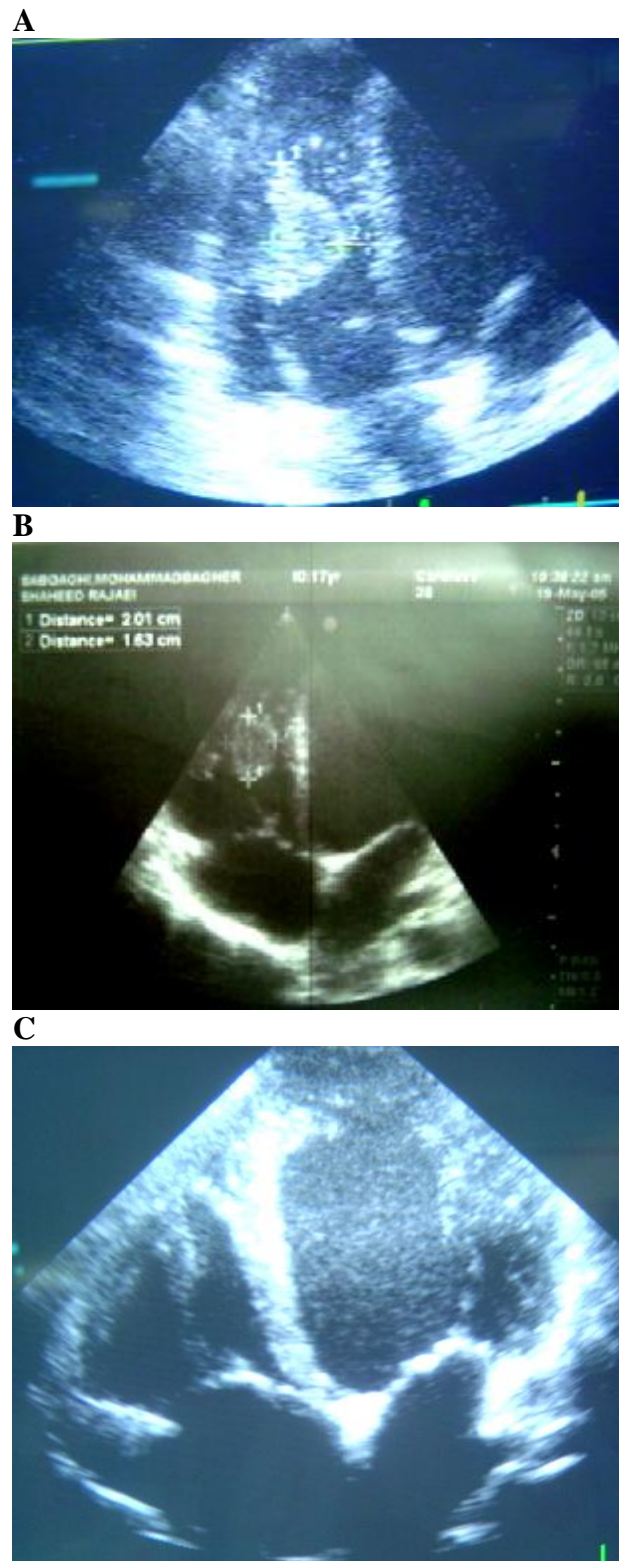


Fig. 1, A. Right ventricular thrombus in Behçet's disease. **B.** Recurrent right ventricular thrombus. **C.** Disappearance of thrombus after 4 months of immunosuppressive therapy

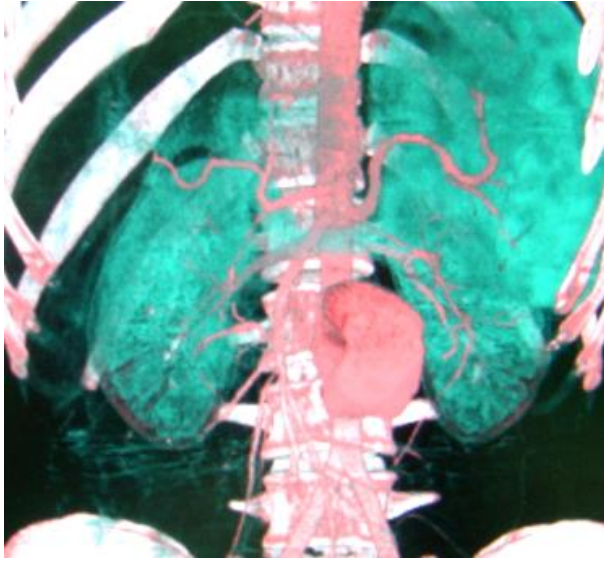


Fig. 2. CT angiography demonstrates pseudoaneurysm of the infrarenal aorta in a 17-year-old boy suffering from Behçet's disease and recurrent right ventricular heart thrombus.

References

- Basaran Y, Degertekin M, Direskeneli H, Yakut C. Cardiac thrombosis in a patient with Behcet's disease: two years follow-up. *Int J Card Imaging* 2000 Oct; 16(5): 377-82.
- Hammami S, Mahjoub S, Ben-Hamda K, Brahem R, Gamra H, Ben Farhat M. Intracardiac thrombus in Behcet's disease: two case reports. *Thromb J* 2005 Jul; 25(3): 9.
- Criteria for Diagnosis of Behcet's Disease. International Study Group for Behcet's Disease. *Lancet* 1990 May 5; 335 (8697): 1078-80.
- Dincer I, Dandachi R, Atmaca Y, Erol C, Caglar N, Oral D. A recurrent right heart thrombus in a patient with Behcet's disease. *Echocardiography* 2001 Jan; 18(1): 15-8.
- Hamza M. Large artery involvement in Behcet's disease. *J Rheumatol* 1987 Jun; 14(3): 554-9.
- Atzeni F, Sarzi-Puttini P, Doria A, Boiardi L, Pipitone N, Salvarani C. Behcet's disease and cardiovascular involvement. *Lupus* 2005; 14 (9): 723-6.
- Lee CW, Lee J, Lee WK, Lee CH, Suh CH, Song CH, Park YB, Lee SK, Won YS. Aortic valve involvement in Behcet's disease. A clinical study of 9 patients. *Korean J Intern Med* 2002 Mar; 17 (1): 51-6.
- Gurgun C, Ercan E, Ceyhan C, Yavuzgil O, Zoghi M, Aksu K, Cinar CS, Turkoglu C. Cardiovascular involvement in Behcet's disease. *Jpn Heart J* 2002 Jul; 43(4): 389-98.
- Ozkan M, Emel O, Ozdemir M, Yurdakul S, Kocak H, Ozdogan H, Hamuryudan V, Dirican A, Yazici H. M-mode, 2-D and Doppler echocardiographic study in 65 patients with Behcet's syndrome. *Eur Heart J* 1992 May; 13 (5): 638-41.
- Higashihara M, Mori M, Takeuchi A, Ogita T, Miyamoto T, Okimoto T. Myocarditis in Behcet's disease -a case report and review of the literature. *J Rheumatol* 1982 Jul-Aug; 9 (4): 630-3.
- Kaseda S, Koiwaya Y, Tajimi T, Mitsutake A, Kanaide H, Takeshita A, Kikuchi Y, Nakamura M, Mayumi H, Komori M, Tokunaga K. Huge false aneurysm due to rupture of the right coronary artery in Behcet's syndrome. *Am Heart J* 1982 Apr; 103 (4 Pt 1): 569-71.
- Eryol NK, Topsakal R, Abaci A, Oguzhan A. A case of atrioventricular complete block due to Behcet's disease. *Jpn Heart J* 2002 Nov; 43 (6): 697-701.
- Gurgun C, Sagcan A, Cinar CS, Yagdi T, Zoghi M, Tekten T, Kultursay H. Right atrial and ventricular thrombi in Behcet's disease: a case report and review of literature. *Blood Coagul Fibrinolysis*. 2000 Jan; 11 (1): 107-10.
- Schmitz-Huebner U, Knop J. Evidence for an endothelial cell dysfunction in association with Behcet's disease. *Thromb Res* 1984 May 15; 34 (4): 277-85.
- Jordan JM, Allen NB, Pizzo SV. Defective release of tissue plasminogen activator in systemic and cutaneous vasculitis. *Am J Med* 1987 Mar; 82 (3): 397-400.
- Hull RG, Harris EN, Gharavi AE, Tincani A, Asherson RA, Valesini G, Denman AM, Froude G, Hughes GR. Anti-cardiolipin antibodies: occurrence in Behcet's syndrome. *Ann Rheum Dis* 1984 Oct; 43 (5): 746-8.
- Vanhaleweyk G, el-Ramahi KM, Hazmi M, Sieck JO, Zaman L, Fawzy M. Right atrial, right

- ventricular and left ventricular thrombi in (incomplete) Behcet's disease. *Eur Heart J* 1990 Oct; 11 (10): 957-9.
18. Yurdakul S, Tuzuner N, Yurdakul I, Hamuryudan V, Yazici H. Gastrointestinal involvement in Behcet's syndrome: a controlled study. *Ann Rheum Dis* 1996 Mar; 55 (3): 208-10.
19. Mogulkoc N, Burgess MI, Bishop PW. Intracardiac thrombus in Behcet's disease: a systematic review. *Chest* 2000 Aug; 118 (2): 479-87.