

ELECTRONIC PAPERS

Late occurrence of fatal aortitis: a complication of *Aspergillus endocarditis* following coronary artery bypass graft surgery

Maryam Esmaeilzadeh^{1*}, Mozhgan Parsaee¹, Mohammad Mehdi Peighambari², Anita Sadeghpour¹, Amir J. Khamooshi³, S. Saeid Hosseini³, and Kambiz Mozaffari⁴

¹Department of Echocardiography, Shaheed Rajaie Cardiovascular Medical and Research Center, Vali-Asr Avenue, Adjacent Mellat Park, PO Box 1996911151, Tehran, Iran; ²Department of General Cardiology, Shaheed Rajaie Cardiovascular Medical and Research Center, Tehran, Iran; ³Department of Cardiac Surgery, Shaheed Rajaie Cardiovascular Medical and Research Center, Tehran, Iran; and ⁴Department of Pathology, Shaheed Rajaie Cardiovascular Medical and Research Center, Tehran, Iran

Received 11 March 2008; accepted after revision 5 July 2008; online publish-ahead-of-print 29 July 2008

KEYWORDS

Aspergillosis;
Coronary artery bypass
grafting;
Endocarditis;
Complication

The most common fungal organism to cause endocarditis is *Candida* which is followed by *Aspergillus*. *Aspergillus endocarditis* can occur in either the native or prosthetic heart valves, usually occurs post-operative after cardiac valve surgery. This case is illustrative of a 49-year-old man with previous history of coronary artery bypass grafting presenting with aortic valve endocarditis which was diagnosed as *Aspergillus endocarditis*. Unfortunately, despite medical and surgical therapy, progressive fatal aortic invasion occurred.

Introduction

The most common fungal organism to cause endocarditis is *Candida* (62%), which is followed by *Aspergillus* (18%).¹ The inoculum for establishing infection is not known, but it is apparent that hosts with normal pulmonary defences very rarely develop disease, despite routine exposure to the organism.²

Aspergillus endocarditis can occur in either native or prosthetic heart valves, usually occurs after cardiac valve surgery. Diagnosis is difficult because blood culture usually remains negative even with extensive disease.³ Even with surgical intervention, long-term survival is limited.

Case report

A 49-year-old-man was referred to our institution with fever for 3 months, dyspnoea, malaise, left leg pain, anorexia, and weight loss. He had a history of coronary artery bypass grafting 2.5 years ago and had a recent vascular surgery twice for arterial emboli in another centre without definite pathology or positive culture.

On physical examination, there was low grade fever and holodiastolic murmur along the left sternal border. The electrocardiogram shows sinus tachycardia with first-degree AV block. Haematology and biochemistry disclosed mild anaemia (haemoglobin = 9.5 g/dL), leukocytosis (WBC = 13 700), eosinophilia (8%), increased erythrocyte sedimentation rate (ESR) up to 105 and C-reactive protein. Serological tests for hepatitis and HIV and all blood cultures were negative.

Transthoracic and transesophageal echocardiography (TEE) revealed moderately enlarged left ventricle with sub-normal ejection fraction (50%), very large (25 × 18 mm) bulky smooth surface mobile vegetation on the non-coronary aortic cusp with ring abscess formation on posterior side of aortic root (Figure 1 and Supplementary material online, Movies S1 and S2) and severe aortic regurgitation secondary to flail aortic valve.

Since homograft valve was not available, the aortic valve was replaced by a mechanical bileaflet valve without root replacement. Histopathological examination demonstrated *Aspergillus* spp. (Figure 2). Immediate treatment with amphotericin B was started; however, the patient remained febrile with elevated ESR and C-reactive protein. Repeat TEE showed multiple vegetations on the aortic valve prosthesis and inside the ascending aorta. So repeat AVR with porcine free style valve and mini-root replacement was

* Corresponding author. Tel: +98 2123921; fax: +98 2122055594.
E-mail address: meszadeh@rhc.ac.ir or m_eszadeh@yahoo.com

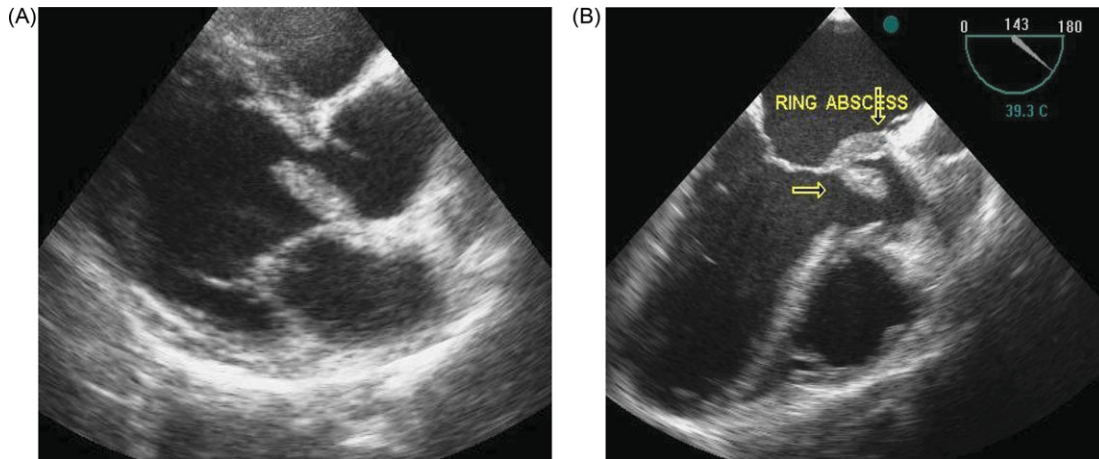


Figure 1 (A) Transthoracic parasternal long-axis view showed very large smooth surface bulky vegetation on left coronary cusp of aortic valve. (B) Transesophageal long-axis view showed the large vegetation and ring abscess (arrows).

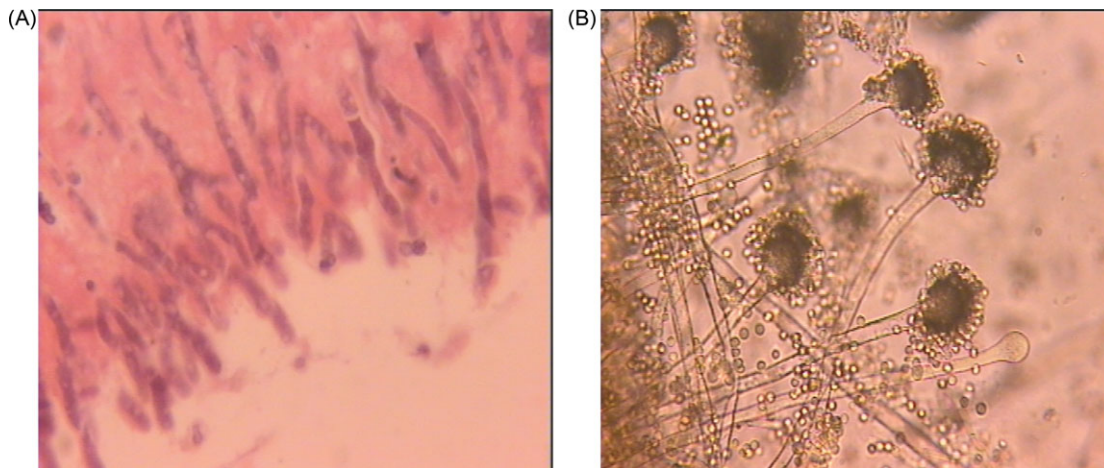


Figure 2 (A) Microscopic section of aortic valve vegetation (H&E staining $\times 400$) consists of acute-angle branching septated hyphae. Fungal elements consistent with *Aspergillus* spp. (B) Septated hyphae with acute angle branching and numerous fruiting bodies (wet-mount smear from cultured specimen).

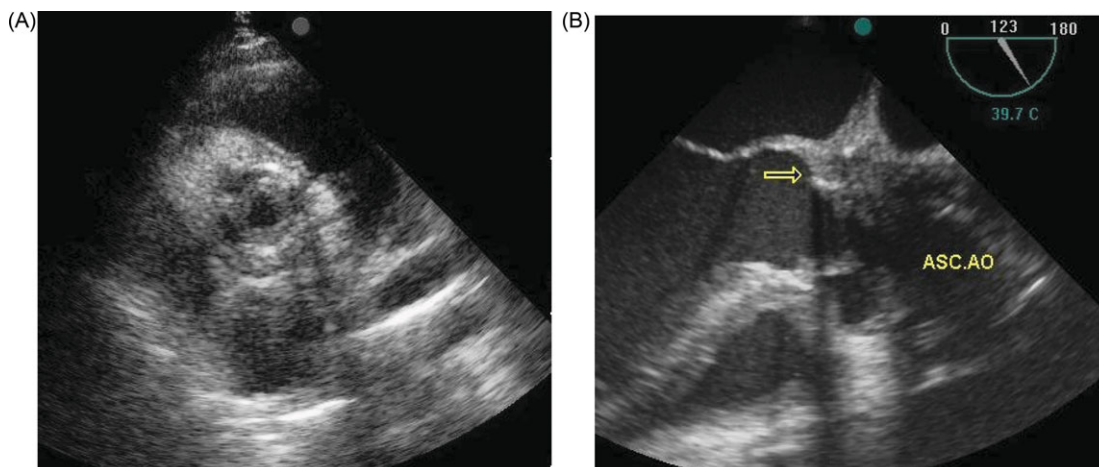


Figure 3 (A) Transthoracic parasternal short-axis view showed much thickened aortic bioprosthesis leaflets with significant obstruction secondary to commissural fusion. (B) Transesophageal long-axis view of aortic valve and ascending aorta revealed severe obliteration and obstruction of ascending aorta by multiple bulky vegetations (arrow).

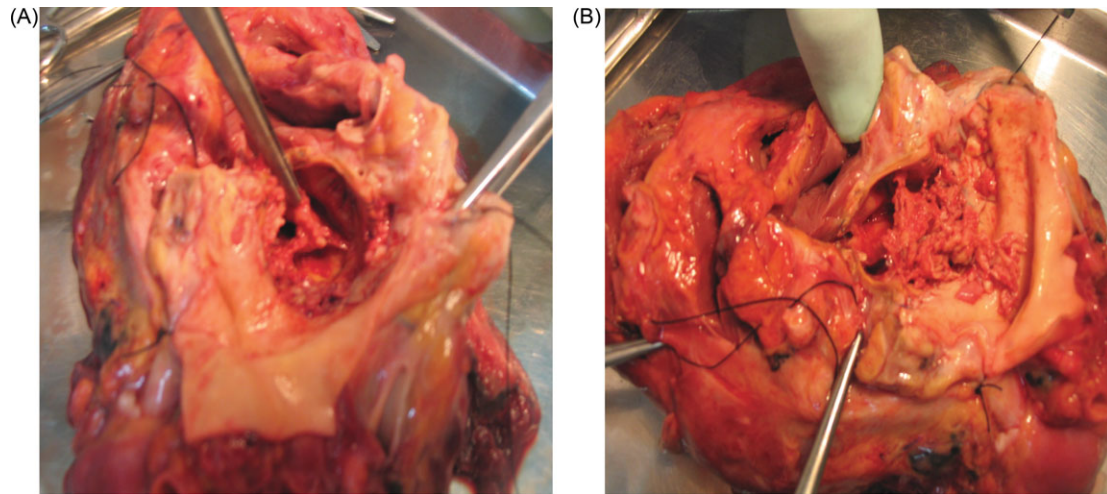


Figure 4 (A) Post-mortem examination showed significant thickening of aortic bioprosthesis. (B) Aortic lumen had been filled by fragile and soft pieces of vegetations.

performed. Seven weeks after the second surgery, TEE showed extensive involvement of bioprosthetic valve and aortic root (Figure 3).

Varicazazole was prescribed but patient abruptly developed acute severe chest pain followed by cardiac arrest not responsive to cardiopulmonary resuscitation. Post-mortem examination revealed significant thickening of bioprosthetic valve leaflets with ring abscess and multiple clusters of vegetations in aortic lumen (Figure 4).

Discussion

Aspergillus endocarditis is rare in hosts with normally functioning immune system and on native heart valves;⁴ however, in our case none of the patients with *Aspergillus endocarditis* after cardiac surgery were immunocompromised.⁵ This suggests that the most important alteration of host defence is probably the surgical procedure itself.⁵

In one study, aspergillosis began 4–24 months after surgery.⁵ Blood cultures are typically negative in aspergillosis³ leading to delayed diagnosis and fatal outcome. The lower extremity emboli as the presenting signs are relatively uncommon presentation, although it has been previously reported.⁶ The management required aggressive medical and surgical approaches. It seems that the aortic damage after cannulation for first cardiopulmonary bypass results to aortic valve endocarditis and incomplete surgical treatment was the leading cause for subsequent aortic wall infection.

Conclusion

Aspergillus endocarditis is an ominous complication typically found after valve or coronary surgery. Echocardiography is a

rapid and reliable technique for early diagnosis and should be considered in patients with prolonged fever and negative blood culture after open-heart surgery irrespective of the post-operative period.

Supplementary data

Supplementary data are available at *European Journal of Echocardiography* online.

Funding

This work was totally funded by Shaheed Rajaie Cardiovascular Medical and Research Center.

Conflict of interest: none declared.

References

1. Knollmana-Ritschel B. Pathology cases for diagnosis case 97–01: *Aspergillus endocarditis* on a native heart valve. August 1997.
2. Mandell GL, Bennett JE, Dolin R. *Principle and Practice of Infectious Diseases*. Elsevier Inc.; 2005:2958–2970 (vol. 4); 992–993 (vol. 2).
3. El-Hamamsy I, Durrleman N, Stevens LM, Perrault LP, Carrier M. *Aspergillus endocarditis* after cardiac surgery. *Ann Thorac Surg* 2005;**80**:359–64.
4. Alvarez JR, Quiroga JS, Taboada CR, Gonzalez AF, Torres FM, Bengochea JG. Cardiac aspergillosis with pedunculated mass in left ventricle. *Tex Heart Inst J* 2004;**31**:439–41.
5. Sanchez-Recalde A, Mate I, Merino JL, Sobrino JA. *Aspergillus aortitis* after cardiac surgery. *J Am Coll Cardiol* 2003;**41**:152–6.
6. Verghese S, Maria CF, Mullaseri AS, Asha M, Padmaja P, Padhye AA. *Aspergillus endocarditis* presenting as femoral artery embolism. *Mycoses* 2004;**47**:252–6.