

Prosthetic Pulmonary Valve Malfunction

Hassan Riahi MD, Majid Maleki MD, FACC,¹
Maryam Esmaeilzadeh, MD, FCAPSC² and Mozhgan Parsaee MD³

Abstract

Prosthetic heart valve thrombosis is a serious complication in which systemic thrombolysis has emerged as a suitable alternative to surgery, especially for right-sided prosthetic valve thrombosis.

We report here the case of a thrombosed Carbomedics Medical prosthetic valve placed in the pulmonary position, in a patient who had undergone total repair of tetralogy of Fallot, which was successfully treated with intravenous thrombolytic therapy with streptokinase.

Key words: prosthetic valve malfunction ■ thrombolytic therapy ■ pulmonary valve replacement

Fig. 1. Fluoroscopic view showing restricted leaflet motion of the prosthetic pulmonary valve.

Since he was considered to be at very high risk for another surgical procedure, he underwent thrombolytic therapy with streptokinase, based on ACC/AHA guidelines for the treatment of right-sided prosthetic heart valve complicated by thrombus. After 24 hours, the fluoroscopic examination showed normal motion of one leaflet that was previously restricted, with the other leaflet still in a fixed position (Fig. 1).

Echocardiography also revealed better but yet abnormal hemodynamic findings, with a peak gradient of 40 mmHg, so thrombolytic therapy was continued for a second 24 hours. After 48 hours, the prosthetic heart valve sound was normally audible on auscultation.

The fluoroscopic examination showed normal motion of both leaflets (Fig. 1) and echocardiography revealed an acceptable function for the mechanical PV with normal hemodynamic findings and peak gradient of 17 mmHg (Fig. 2). The patient was discharged from hospital free of symptoms without any complications and with recommendation for precise anticoagulation therapy.

showed normal motion of both leaflets (Fig. 1) and echocardiography revealed an acceptable function for the mechanical PV with normal hemodynamic findings and peak gradient of 17 mmHg (Fig. 2). The patient was discharged from hospital free of symptoms without any complications and with recommendation for precise anticoagulation therapy.

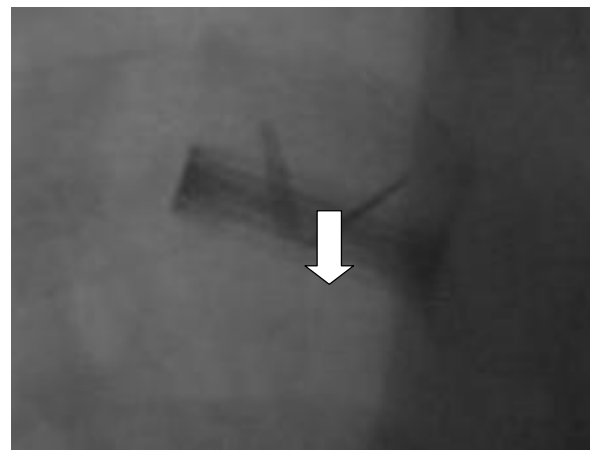
Case report

A 28 year old male, a known case of tetralogy of Fallot, was admitted to the hospital because of a subjective diminished prosthetic heart valve sound. A palliative right Blalock - Taussig shunt had been performed when he was 1 year old; followed by a total repair at the age of 7 years, and a pulmonary valve replacement with a prosthetic heart valve (Carbomedics 25mm) for severe pulmonary insufficiency 4 years ago. He had no cardiopulmonary symptoms and his physical examination was unremarkable except for an apparent decrease in prosthetic heart valve sound.

Fluoroscopic examination of the prosthetic valve showed a fixed leaflet in incomplete closure position and the other with a range of motion of only 20 to 30 degrees (Fig. 1).

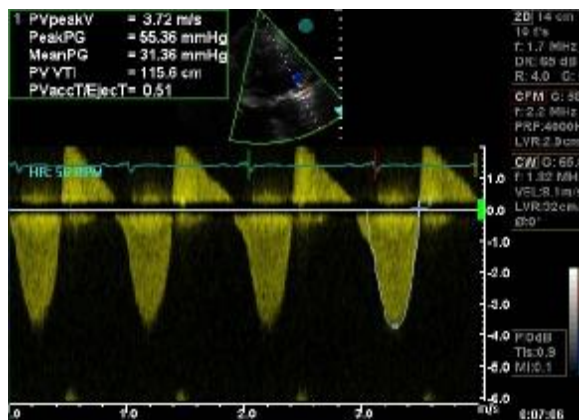
Transesophageal echocardiography revealed bileaflet prosthetic pulmonary valve with incomplete closure of posterior leaflet caused by a 7x8 mm thrombus leading to at least moderate transvalvular regurgitation and a peak gradient of 55 mmHg (Fig. 2).

(1) Professor of Cardiology, (2) Associate Professor of Cardiology
From Shaheed Rajaie Cardiovascular Medical and Research Center
Corresponding author: Hassan Riahi, MD, Resident of Cardiology
and Research Center, Vali Asr St, Mellat Park, Tehran, Iran
E-mail address: amirpeyk@yahoo.com Tel:+98-21-21212121



ular Medical

Fig. 1 Cinefluoroscopy of the pulmonary valve before streptokinase infusion (upper row), after 24 hours receiving streptokinase (middle row) and after 48 hours streptokinase therapy (lower row). In the left column the prosthetic valve is shown in systole and in the right column is shown in diastole. Before streptokinase infusion, one leaflet is fixed (large arrow), and the mobility of the other leaflet is severely restricted (small arrow). After 24 hours thrombolytic therapy (middle row), excursion of the semimobile leaflet is somewhat better but the other leaflet is still fixed & after 48 hours therapy (lower row), there is normal excursion of the both leaflets, shown in systole and diastole



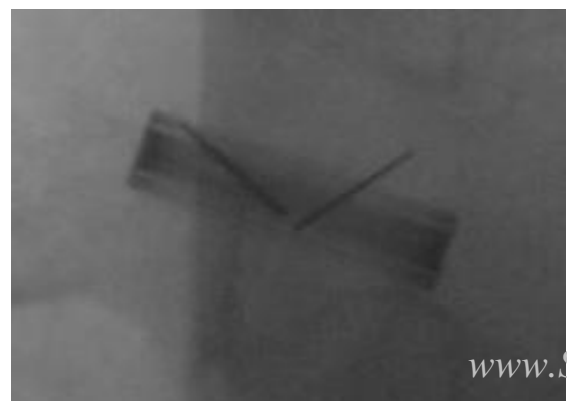
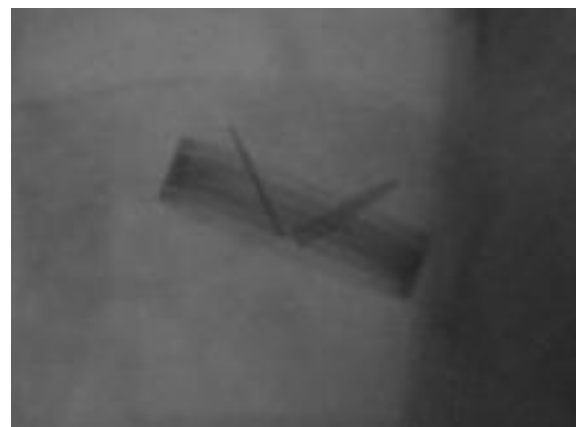
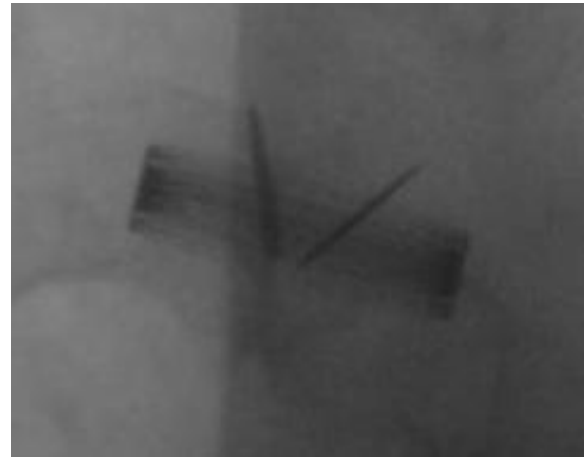
gradient, 17 mmHg; mean

Fig. 2. Continuous-wave Doppler showing peak velocity of 3.72 m/sec across the pulmonary prosthesis before streptokinase infusion (above, peak gradient, 55 mmHg; mean gradient, 31 mmHg), and after infusion (below, peak gradient, 11 mmHg).

Discussion

Pulmonary valve replacement for severe chronic pulmonary insufficiency after total surgical correction of tetralogy of Fallot is indicated in some situations such as substantial right ventricular dilation or dysfunction, exercise intolerance or sustained arrhythmia. The coexistence of substantial left ventricular dysfunction or QRS duration equal to or more than 180msec offers additional support when other indications are present.

In selected patients, excellent clinical results have been reported¹, but thrombosis remains a frequent cause of morbidity and mortality, with incidence as high as 50% for right-sided placement of St. Jude Medical prosthetic valves in patients with congenital heart



2. Miyamura H, Kanazawa H, Hayashi J, Eguchi S. Thrombosed St. Jude Medical valve prosthesis in the right side of the heart in patients with tetralogy of Fallot. *J Thorac Cardiovasc Surg* 1987; 94: 148-50.
3. Fyfe DA, Taylor AB, Kline CH, Sade RNI, Gillette PC. Doppler echocardiographic evaluation of streptokinase lysis of thrombosed right-sided St. Jude Medical valves in patients with congenital heart defects. *Am Hear J* 91; 121: 1156-60.
4. Okita Y, Miki S, Kusuhara K, Ueda Y, Tahata T, Sakai T. Replacement of thrombosed St Jude Medical prosthesis in pulmonary position after repeated thrombolytic therapy. *Thorac Cardiovasc Surg* 1992; 40: 99-101.
5. Manteiga R, Souto JC, Altes A, et al. Short-course thrombolysis as the first line therapy for cardiac valve thrombosis. *J Thorac Cardiovasc Surg* 1998; 115: 780-4.

disease.^{2,3} Factors that may contribute to thrombus formation include inadequate anticoagulation therapy, paradoxical motion of the right ventricular outflow tract, reduced contractility, and ventricular arrhythmias.^{2,10}

The traditional treatment of prosthetic heart valve thrombosis has been thrombectomy or valve replacement, however reported mortality rates are between 8% and 60%⁵, depending on the clinical status.

Reports of successful thrombolysis in patients with prosthetic valve thrombosis have allowed such therapy to emerge as an alternative to surgery, although there is a real risk of emboli.⁶

The 1st case of successful thrombolysis in a valve prosthesis was reported by Luluaga and colleagues in 1971; they used intravenous streptokinase in a critically ill patient with thrombosis of a Starr-Edwards tricuspid valve.⁷ Recent studies consider fibrinolysis the first line therapy in right-sided prosthetic heart valve thrombosis and an alternative treatment of left-sided prosthetic heart valve thrombosis^{6,8} and streptokinase and tissue plasminogen activator are considered the thrombolytic agents of choice.^{6,8} A recent study showed that accelerated streptokinase infusion is not better than the standard infusion for left-sided prosthetic valve thrombosis.⁹

Because prosthetic valve replacement in the pulmonary position is uncommon, experience with systemic lytic therapy for this valve is limited. Streptokinase has been the most common thrombolytic agent employed in pulmonary prosthetic thrombosis,^{2,5,10} although there are cases with rtPA⁵ and urokinase,⁴ most of which were successful and without any complications.

Although thrombolytic therapy is very effective in prosthetic pulmonary valve thrombosis, some case reports consider that mechanical prosthetic valves are not advisable for use in the pulmonary position, and in some cases the mechanical prosthesis has been replaced by a bioprosthesis due to recurrent prosthetic dysfunction⁴, although we have seen many premature degenerative changes of porcine valves in the pulmonary position.

In patients with a mechanical pulmonary valve, more aggressive anticoagulation and the use of antiplatelet drugs should be considered.¹⁰

References

1. Misbach GA, Turlev K, Ebert PA. Pulmonary valve replacement for regurgitation after repair of tetralogy of Fallot. *Ann Thoracic Surg* 1983; 36: 684-91.