



Apical Hypertrophic Cardiomyopathy in Association with Pulmonary Artery Hypertension

Mehdi Peighambari¹, Mozghan Parsaei¹, Anita Sadeghpour¹, Azin Alizadehasl^{2*}

¹Rajaie Cardiovascular Medical and Research Center, Tehran University of Medical Sciences, Tehran, Iran

²Cardiovascular Research Center, Tabriz University of Medical Sciences, Tabriz, Iran

ARTICLE INFO

Article Type:

Case Report

Article History:

Received: 4 May 2012

Accepted: 29 Aug 2012

ePublished: 23 Sep 2012

Keywords:

Apical Hypertrophic Cardiomyopathy

Pulmonary Artery Hypertension

Echocardiography

ABSTRACT

Apical Hypertrophic Cardiomyopathy is an uncommon condition constituting 1% -2% of the cases with Hypertrophic Cardiomyopathy (HCM) diagnosis. We interestingly report two patients with apical hypertrophic cardiomyopathy in association with significant pulmonary artery hypertension without any other underlying reason for pulmonary hypertension. The patients were assessed by echocardiography, cardiac catheterization and pulmonary function parameters study.

Introduction

An unusual form of hypertrophic cardiomyopathy (HCM) localized to the left ventricular (LV) apex was first described in 1976. The diagnostic criteria for apical HCM (AHCM) included presence of asymmetric LV hypertrophy, confined predominantly to the LV apex, with an apical wall thickness ≥ 15 mm and a ratio of maximal apical to posterior wall thickness ≥ 1.5 , based on an echocardiogram or magnetic resonance imaging. Consisting 1%-2% of the HCM cases, AHCM is distinctly uncommon in other parts of the world. In Japan, this apical variant of HCM constitutes about 25% of patients with HCM.¹⁻³ In this case study, we report two female patients with AHCM in association with significant pulmonary artery hypertension with no explainable reason for pulmonary hypertension. No similar case could be found in the literature review.

Case Report

Two female patients were referred to our center with complaints of dyspnea on exertion and NYHA function class of 1 to 2. Their electrocardiograms (ECG) showed sinus rhythm with giant negative T waves mostly noted in leads V3-V6 measuring 6-12 mm in depth; one of the taken ECGs is presented in Figure 1.

Transthoracic echocardiogram revealed a grossly thickened LV apical myocardium with systolic obliteration of the apical portion of the LV cavity (Figure 2). LV apical thickness of 20 and 23 mm was reported in two patients while the diameters in septal and posterobasal thickness were normal. No systolic anterior motion of the anterior

mitral leaflet or mitral regurgitation could be seen.

On Doppler evaluation of mitral inflow velocities, the ratio between early diastolic flow (E) and atrial systolic flow (A) was less than 1 in both patients. Complete transthoracic echocardiographic examination revealed significant pulmonary artery hypertension (pulmonary artery pressures were equal to 50 and 65 mmHg in two patients). No other abnormal finding was observed in echocardiographic assessment.

Furthermore, strain and strain rate studies confirmed muscular hypertrophy and AHCM in our patient which were in differential diagnosis with apical cardiac tumors, LV apical thrombus, and endomyocardial fibrosis (EMF).

These patients underwent left and right cardiac catheterization through the left femoral arterial and venous approach. The pulmonary arterial pressure values were 48/18 mmHg and 50/24 mmHg and the mean pulmonary capillary wedge pressure values were 23 mmHg and 20 mmHg. In addition, contrast ventriculography showed a specific LV "spade-like" configuration while coronary angiogram revealed normal coronary arteries in both patients.

Discussion

AHCM is mostly considered of a sporadic nature; however, a few families with autosomal dominant inheritance have been reported.³ Apical HCM could mimic other conditions including apical cardiac tumors, LV apical thrombus, EMF and coronary artery disease. The strain and strain rate echocardiographic studies that we performed differentiated apical HCM from LV apical masses (thrombus or tumor).

*Corresponding author: Azin Alizadehasl, E-mail: alizadeasl@yahoo.com

LV angiogram showed apical obliteration only during systole phase in our patients, whereas in EMF, apical obliteration occurs in systole and diastole phases; also coronary angiography revealed normal coronary arteries.⁴⁻⁸

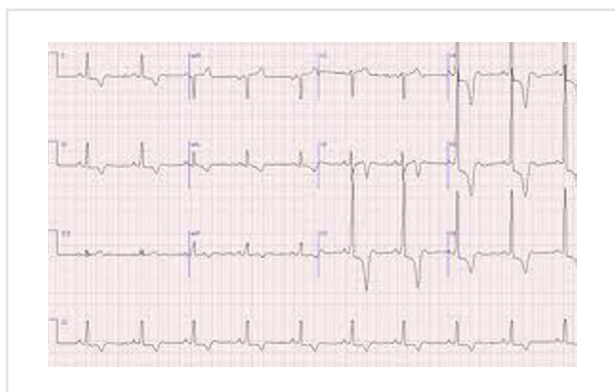


Figure 1. Electrocardiogram showing sinus rhythm with giant negative T waves were noted in leads V3–V6

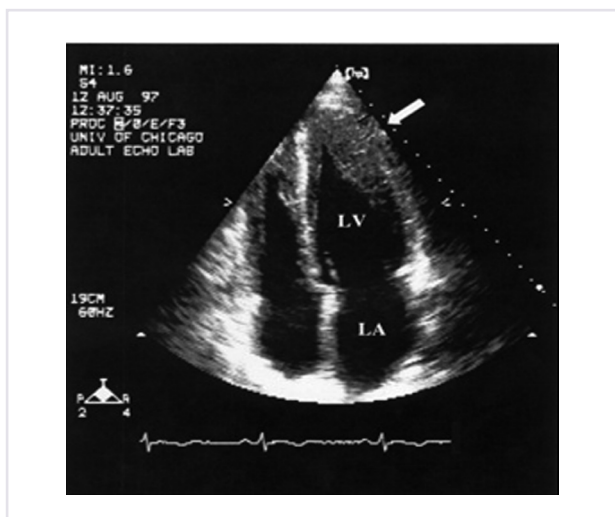


Figure 2. On 2-dimensional echocardiography, an apical 4-chamber view of the left ventricle showing hypertrophy of the apex in an "ace-of-spades" configuration

Echocardiographic assessment constantly shows normal or hyperdynamic LV systolic function in patients with AHCM. However, diastolic function is abnormal with slow early ventricular filling associated with increased dependence on late diastolic filling by atrial contraction. This may lead to left atrial dilatation and pulmonary hypertension.^{8,9}

These patients are however unique in having a moderate to severe form of pulmonary hypertension along with AHCM. In our opinion, the mild diastolic LV dysfunction secondary to AHCM that was seen in our patients may establish mild or maximum mild to moderate pulmonary hypertension; however, we faced unexplained near severe increase in pulmonary artery pressure; all echocardiographic, catheterism and pulmonary function parameters were assessed in both patients. There may be an association between AHCM and pulmonary hypertension. However, we could not find any similar case

in the literature review.

References

1. Kitaoka H, Doi Y, Casey SA, Hitomi N, Furuno T, Maron BJ. Comparison of prevalence of apical hypertrophic cardiomyopathy in Japan and the United States. **Am J Cardiol** 2003;92:1183-6.
2. Arad M, Penas-Lado M, Monserrat L, Maron BJ, Sherrid M, Ho CY, et al. Gene mutations in apical hypertrophic cardiomyopathy. **Circulation** 2005;112:2805-11.
3. Choi EY, Rim SJ, Ha JW, Kim YJ, Lee SC, Kang DH, et al. Phenotypic spectrum and clinical characteristics of apical hypertrophic cardiomyopathy: multicenter echo-Doppler study. **Cardiology** 2008; 110:53-61.
4. Veinot JP, O'Murcho B, Tazelaar HD, Orszulak TA, Seward JB. Cardiac fibroma mimicking apical hypertrophic cardiomyopathy: a case report and differential diagnosis. **J Am Soc Echocardiogr** 2008; 9:94-9.
5. Thanigaraj S, Pérez JE. Apical hypertrophic cardiomyopathy: echocardiographic diagnosis with the use of intravenous contrast image enhancement. **J Am Soc Echocardiogr** 2000;13:146-9.
6. Spirito P, Autore C. Apical hypertrophic cardiomyopathy or left ventricular non-compaction? A difficult differential diagnosis. **Eur Heart J** 2007;28:1923-4.
7. Hassan WM, Fawzy ME, Al Helaly S, Hegazy H, Malik S. Pitfalls in diagnosis and clinical, echocardiographic, and hemodynamic findings in endomyocardial fibrosis: a 25-year experience. **Chest** 2005; 128:3985-92.
8. Duygu H, Zoghi M, Nalbantgil S, Ozerkan F, Akilli A, Akin M, et al. Apical hypertrophic cardiomyopathy might lead to misdiagnosis of ischaemic heart disease. **Int J Cardiovasc Imaging** 2008; 24:675-81.
9. Eriksson MJ, Sonnenberg B, Woo A, Rakowski P, Parker TG, Wigle ED, et al. Long-term outcome in patients with apical hypertrophic cardiomyopathy. **J Am Coll Cardiol** 2002; 39:638-45.