

Accessory Mitral Valve Tissue in Mirror-Image Dextrocardia

M. Shojaeifard, MD; M. Maleki, MD, FACC, A.A; Yusefi, MD; F. Noohi, MD, FACC, FESC; Z. Ojaghi Haghighi, MD, FACC

Abstract

A 20-year-old man was referred to us for further evaluation due to infective endocarditis. He had mirror-image dextrocardia with visceral situs inversus. He had a history of dyspnea on exertion (NYHA class II) of several years' duration with no new onset symptoms. On physical examination, he had no peripheral stigmata of infective endocarditis. Laboratory examination showed a normal erythrocyte sedimentation rate with normal hemoglobin. Three separate sets of blood cultures obtained over a 24-hour period and cultures were negative in aerobic and anaerobic media. Transthoracic and transesophageal echocardiographic studies showed mirror-image dextrocardia with total situs inversus as well as accessory mitral valve tissue with chordal attachment to the posteromedial papillary muscle with no significant LVOT obstruction (Figs. 1,2) but resulting in mild to moderate aortic insufficiency (Fig.3). There was also aneurysmal dilation of the membranous part of the interventricular septum with a residual pouch and no residual ventricular septal defect according to computational fluid dynamics and contrast studies (Fig 4). There was no other concomitant abnormality. The patient was discharged in good physical condition (*Iranian Heart Journal 2011; 12 (3):60-63*).

Keywords: Dextrocardia ■ Accessory mitral valve ■ Mirror image

Case Report

A 20-year-old man was referred to Rajaei Cardiovascular, Medical and Research Center for further evaluation of infective endocarditis. He had dyspnea on exertion (NYHA class II) and no history of fever or anorexia or weight loss. He had no fever at admission time and during hospitalization. On cardiac examination, point of maximal impulse was palpated at the right mid-clavicular line at approximately the 5th intercostal space.

Abdominal and visceral situs was inversus; this was confirmed by abdominal sonography. No evidence of organomegaly or any peripheral stigmata of infective endocarditis was seen. In laboratory examination, he had normal ESR (3 cm/s), normal hemoglobin (14.4 mg/dl), and no leukocytosis. Blood cultures were negative in aerobic and anaerobic media.

Transthoracic and transesophageal echocardiographic studies showed mirror-image dextrocardia with total situs inversus.

Received Apr. 21, 2011; Accepted for publication May. 19, 2011

From the Department of Echocardiography, Rajaei Cardiovascular, Medical and Research Center, Tehran, Iran

Majid Maleki M.D.FACC

Professor of Cardiology, Head of Echocardiography Department Rajaei Cardiovascular Medical and Research Center Vali Asr Avenue, Near Park-e Mellat Tehran, Iran

Tel: +98 21 22055594

Fax: +98 21 22055594

There was mild to moderate left ventricular enlargement with moderate systolic dysfunction (LVEF=35%), the right ventricle had a normal size and systolic function, and there was a highly mobile tissue (2.5 cm) at the ventricular aspect of the anterior mitral valve leaflet with chordal attachment to the posteromedial papillary muscle, suggestive of accessory mitral valve tissue. Furthermore, there was protrusion of the accessory mitral valve tissue into the left ventricular outflow tract (LVOT) with no significant LVOT obstruction (LVOT gradient with PPG=20 mmHg) but resulting in mild to moderate aortic insufficiency. Also, there was aneurysmal dilation of the membranous part of the interventricular septum with a residual pouch and no residual ventricular septal defect according to computational fluid dynamics and contrast studies. There was no other concomitant abnormality. The patient was discharged in good physical condition.

Discussion

Accessory mitral valve tissue is a very rare congenital anomaly of the embryologic development of the endocardial cushion and is associated with aortic regurgitation, LVOT obstruction,¹ and occasionally cardiac arrhythmias.⁴ This anomaly is usually accompanied by complex congenital abnormalities but is rarely seen as an isolated anomaly. This tissue is attached by the chordae tendineae to a normal papillary muscle and is protruded into the LVOT during systole.³ The most common symptomatic presentation is LVOT obstruction due to the continued growth of the fibrous tissue in the LVOT region. The resultant complications are dyspnea on exertion, chest pain, syncope, and rarely cerebrovascular accident.² Echocardiography is diagnostic. Patients with significant LVOT obstruction should undergo surgery but prophylactic removal of the accessory tissue is not recommended in asymptomatic mild

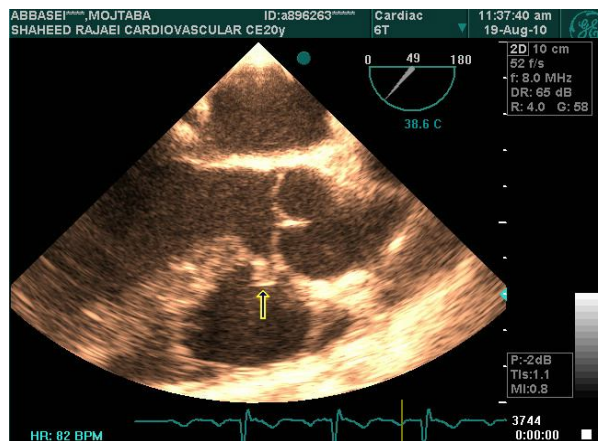
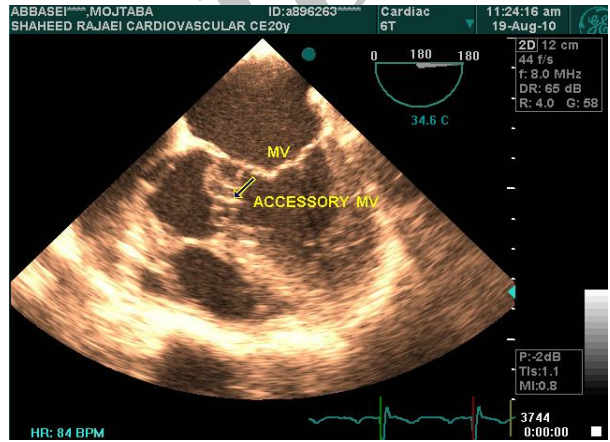
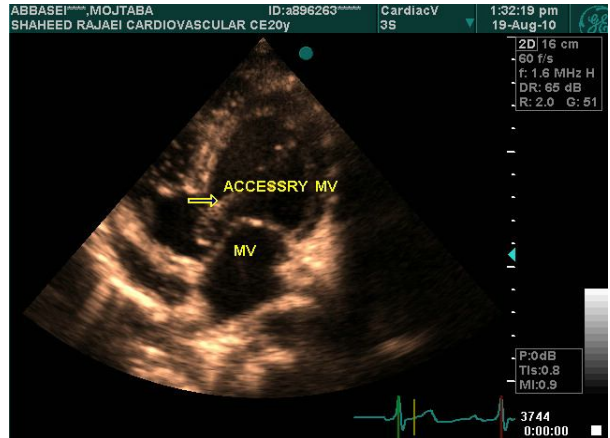
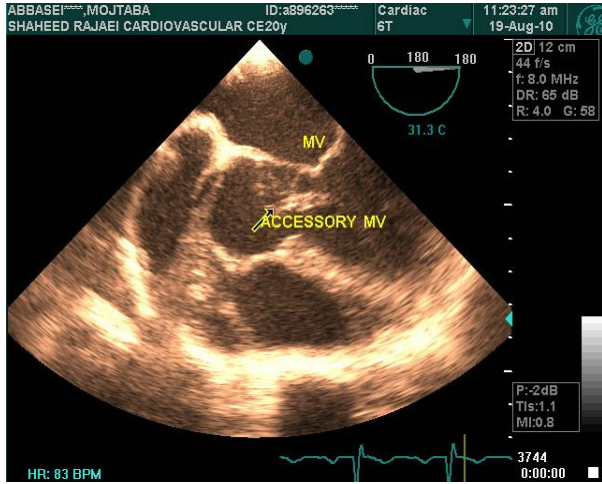
obstruction with no other associated congenital anomalies.² These patients should be followed up by repeated echocardiographic examinations for progressive LVOT obstruction.²

In our patient, there was a highly mobile fibrous tissue (2.5 cm) at the ventricular aspect of the anterior mitral valve leaflet with chordal attachment to the posteromedial papillary muscle. This tissue was completely different from the sub-aortic membrane and protruded into the LVOT region with no significant LVOT obstruction (LVOT gradient with PPG=20 mmHg) but giving rise to mild to moderate aortic insufficiency.

Conclusion

Accessory mitral valve tissue is a rare congenital anomaly and is reported rarely in the world (about two cases per annum). Since 1963, only 78 cases have been reported in the literature.⁵ This anomaly is mostly accompanied by other complex congenital anomalies. It is usually attached to one of the cusps of the normal mitral valve, the chordae tendineae, and then to the posterior papillary muscle, which may cause a high-pressure gradient between the left ventricle and the aorta.⁶ The most common complications are LVOT obstruction, aortic regurgitation, and arrhythmia. Our patient had mirror-image dextrocardia with no other concomitant cardiac lesion. Only there was aneurysmal formation of the membranous part of the interventricular septum with a residual pouch and no residual ventricular septal defect according to computational fluid dynamics and contrast studies. A case was presented in *European Journal of Cardiothoracic Surgery*, in which an accessory mitral valve tissue was associated with situs inversus and reported in an elderly patient with coronary artery disease. The patient underwent coronary bypass surgery, during which the accessory mitral valve tissue was removed.

In our patient, there was no complication requiring interventional procedures, no significant LVOT obstruction, and no significant aortic regurgitation.



Archive

References

1. Antonio D'Aloia, Enrico Vizzardi, Ermanna Chiari, Francesco Fracassi, Dynamic mild subaortic left ventricular obstruction caused by an accessory mitral valve attached to the anterior mitral valve in a young pregnant woman, *European Journal of Echocardiography* .Volume9, Issue1, 2007.
2. Senay Funda Biyikoglu, Yesim Guray, Sezgin Ozturk, Omac Tufekcioglu, Asymptomatic accessory mitral valve tissue diagnosed by echocardiography, *The Anatolian Journal of Cardiology*, 2008. W G Meldrum-Hanna, T B Catmill, R E Hawker, J M Celemajer, C M Wright, Accessory mitral valve tissue causing left ventricular outflow tract obstruction, *British Heart Journal*, 1986; 55: 376-80.
3. Jun Sono, Roxane McKay, Robert Marnold, Accessory mitral valve leaflet causing aortic regurgitation and left ventricular outflow tract obstruction, *British Heart Journal*, 1988; 59:491-7.
4. Hiroshi Izumoto, Kazuaki Ishihara, Masaaki Ogawa, Yutaka Fujii, Kotaro Oyama and Kohei Kawazoe, Nonobstructing Accessory Mitral Valve Tissue and Ventricular Septal Defect, *The Annals of Thoracic Surgery*, Volume 62, Issue 6, December 1996: 1846-1848

Archive of SID