

Hydatid Cyst Mimicking Heart Tumor

Mozhgan Parsaee MD¹; Bahram Mohebbi MD²; Maryam Shojaeifard MD¹; Feridoun Noohi MD, FESC, FACC³; Ahmad Mohebbi MD, FCAPSC, FACC³; Hosseinali Bassiri MD⁴; Saeid Hosseini MD⁵; Mohammad Hasan Ghafari Nejad MD⁶; Kambiz Mozaffari MD⁷; Ali Mohamadzadeh MD⁸

Abstract

We present two women who lived in a rural community. The presence of a semi-solid mass, a hydatid cyst or tumor, in the heart was diagnosed by echocardiography, computed tomography, and Magnetic Resonance Imaging. The hydatid cyst was seen during surgery. Pathological examination confirmed an infected hydatid cyst (*Iranian Heart Journal 2011; 12 (3):51-56*).

Keywords: Cardiac Hydatid Cyst ■ Echocardiography ■ Magnetic Resonance Imaging

The hydatid cyst is a tissue parasitic infection by *Echinococcus granulosus*.

The hydatid cysts can grow in any site of the human's body, but the most common locations are the liver (65%) and the lungs (25%).¹ The cardiac hydatid cyst is seen rarely, and cardiac involvement occurs in about 0.5-2% of all cases of hydatid disease.²³ The cyst is mostly located in the left ventricle (55-60%), followed by right ventricle (15%), pericardium (8%), left atrium (8%), pulmonary artery (6%), and interventricular septum (5-9%).⁴

The major route of cardiac hydatid cyst infection is invasion to the myocardium through the coronary artery circulation, so the left ventricle is more often involved because of the left coronary artery system dominance.⁵

Case Presentation

Case 1

We present a 25-year-old woman from the rural community who complained of exertional dyspnea (functional class II) and pleuritic chest pain of 4 days' duration before admission. She had no complaints of cough, fever, or hemoptysis.

1- Assistant Professor of Cardiology, Rajaie Cardiovascular, Medical and Research Center, Tehran University of Medical Sciences, Tehran, Iran.

2- Fellowship of Echocardiography, Rajaie Cardiovascular, Medical and Research Center, Tehran University of Medical Sciences, Tehran, Iran.

3- Professor of Cardiology, Rajaie Cardiovascular, Medical and Research Center, Tehran University of Medical Sciences, Tehran, Iran.

4- Associate Professor of Cardiology, Rajaie Cardiovascular Medical and Research Center, Tehran University of Medical Sciences, Tehran, Iran.

5- Associate Professor of Cardiac Surgery, Heart Valve Disease Research Center, Rajaie Cardiovascular, Medical and Research Center, Tehran University of Medical Sciences, Tehran, Iran.

6- Associate Professor of Cardiac Surgery, Rajaie Cardiovascular, Medical and Research Center, Tehran University of Medical Sciences, Tehran, Iran.

7- Assistant Professor of Pathology, Rajaie Cardiovascular, Medical and Research Center, Tehran University of Medical Sciences, Tehran, Iran.

8- Assistant Professor of Radiology, Rajaie Cardiovascular, Medical and Research Center, Tehran University of Medical Sciences, Tehran, Iran.

*Corresponding Author: Feridoun Noohi, MD, FESC, FACC

Address: Rajaie Cardiovascular, Medical & Research Center, Vall-Asr Ave., Niyayesh Blvd. Tehran, Iran

Postal Code: 1996911151 Phone: (+98-21) 2392-2580 Fax: (+98-21)2205-5594 Email Address: r00dbar@yahoo.com

In addition, she had unremarkable past medical history and her drug history revealed no history of oral contraception pill (OCP) consumption. On examination, she had no respiratory distress, her blood pressure was 125/80mm Hg, her pulse was 78 beats per minute, and her temperature was 36.8⁰C. Heart examination revealed normal heart sounds and a mid systolic murmur (Grade: II/VI) in the lower sternal border without any radiation, and remaining of examination was normal. electrocardiography showed normal sinus rhythm and inverted T wave in leads II, III, aVF, and V1-V6. Laboratory findings on admission revealed ESR=28 mm/hour, Hb=10.7 g/dL, WBC=17000/ μ L (PMN=88%, lymph=8%, mixed monocyte and eosinophil=4%); normal platelet count, LFT, RFT; and increased D-Dimer (2710 ng/mL). Serological screening for Echinococcosis by enzyme-linked immunosorbent assay (ELIZA) was negative. Transthoracic (Figure 1a) and transesophageal (Figure 1b) echocardiographic examinations showed a large (3x2.5 cm) heterogeneous mass in the RV apex with no other mass in the LV apex or other heart chambers. Pulmonary artery pressure was normal (25 mmHg). There was small pericardial effusion. Multi-Slice Spiral CT Angiography of the pulmonary artery revealed normal main, right and left pulmonary arteries and intra-parenchymal branches without evidence of intraluminal filling defect or thromboembolism. There was no evidence of pulmonary infarct or pleural reaction. There was a hypodense mass lesion at the apical part of the RV chamber with a mild degree of pericardial reaction.

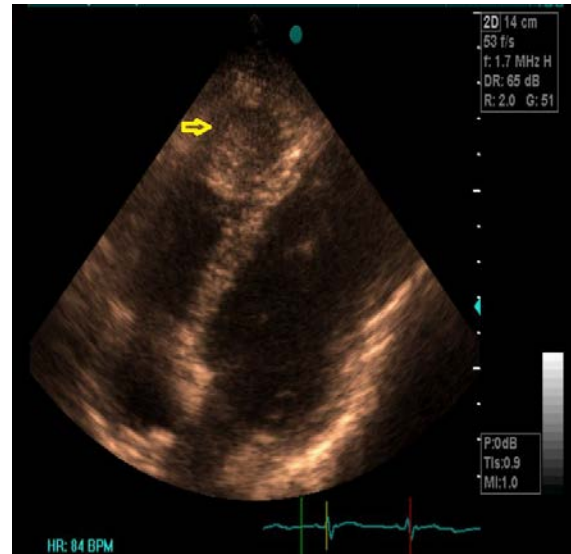


Fig. 1a: Two-dimensional transthoracic echocardiogram in the apical four-chamber view shows a large (3x2.5 cm) heterogeneous mass in the right ventricular apex (yellow arrow)

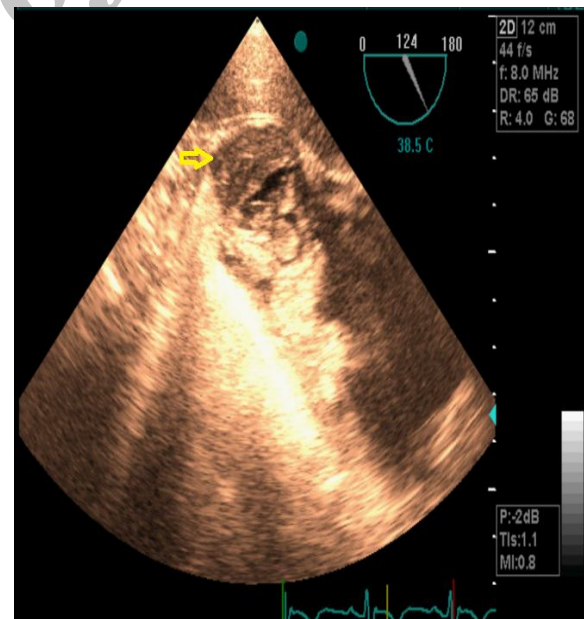


Fig. 1b: Two-dimensional transesophageal echocardiogram in the transgastric view shows a large semisolid mass in the right ventricular apex (yellow arrow)

The mediastinal structures did not show abnormality.

Dynamic cardiac MRI with gadolinium study was done (Fig. 2), demonstrating a large, fixed, lobulated, heterogeneous and well-defined RV apex mass with extension to the RV infero-apical segment and close contact to the right-sided apicoseptal segment (size=2.7x4.2cm) with bulging toward the pericardial space.

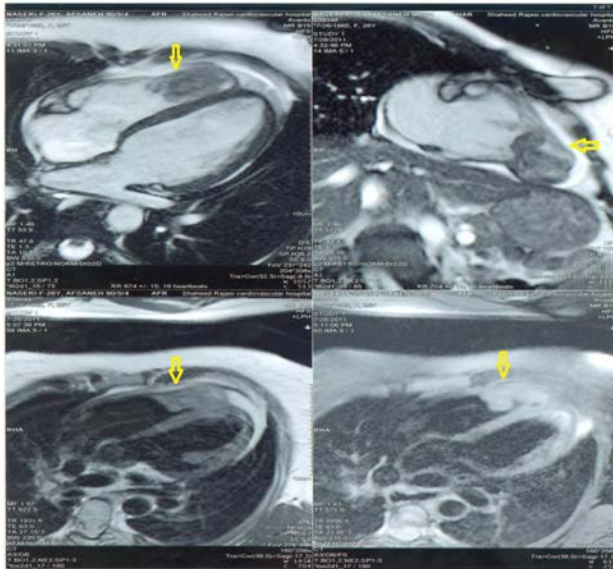


Fig. 2. Dynamic MRI with Gadolinium showed semi solid mass in Right ventricular apex (yellow arrows)

There was evidence of mass edematous component, mild mass perfusion, mild mass enhancement and no evidence of a mass in the fat component.

Multi-Slice Spiral abdominal and pelvic CT scan with IV and oral contrast media were performed, and they were within normal limits.

On the third day of hospital admission, the patient developed fever ($T=38^{\circ}\text{C}$) without change in the examination findings. Antibiotic therapy was started. The patient's general condition improved and she was scheduled for surgical mass resection on the sixth day of hospital admission. Surgery was

performed successfully, and the first diagnosis of the surgeon was an infected hydatid cyst because of a two-layered collapsing mass appearance along with fetid smell (Fig. 3). Pathology examination confirmed the hydatid cyst diagnosis. Albendazole was started after the operation to prevent recurrences.

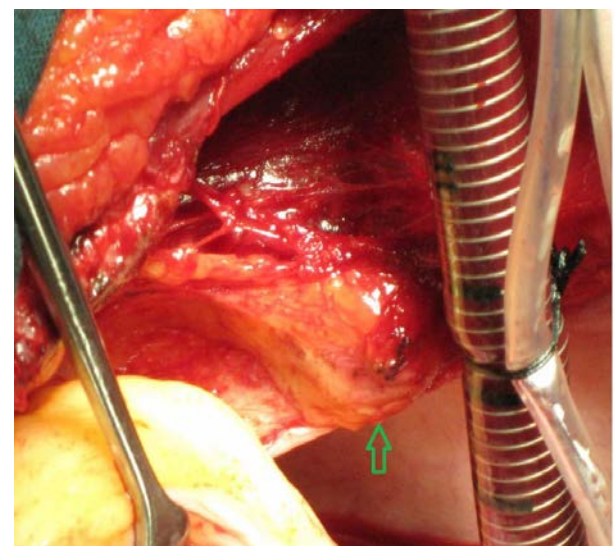
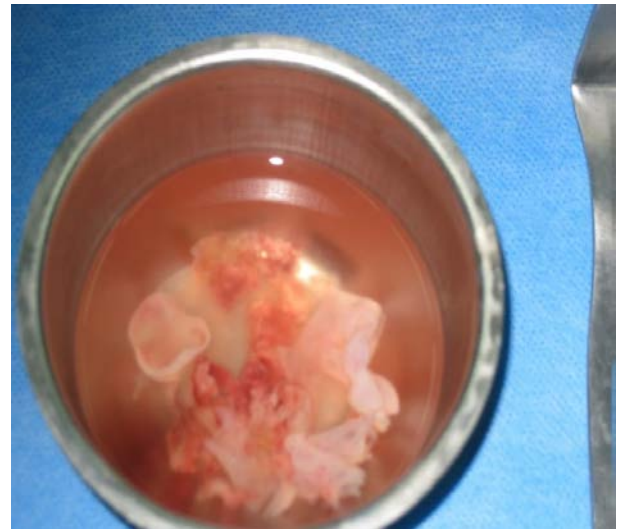


Fig. 3. Hydatid cyst natures of right ventricle apical mass on operative time (green arrows)

Case 2

We present a 47-year-old woman with a history of surgery for lung hydatid cyst 2.5

years previously. Her follow-up chest CT had revealed a mass in the RA, and the patient was referred for further evaluation. She was asymptomatic. On examination, she had no respiratory distress. Her blood pressure was 110/85mm Hg, pulse 82 beats per minute, and temperature 36.4 °C. There was a scar of previous thoracotomy on chest examination. Heart examination revealed normal heart sounds and a mid systolic murmur (Grade: II/VI) in the lower sternal border without any radiation; and the remainder of the examination was normal.

Electrocardiography showed normal sinus rhythm. Laboratory findings on admission revealed ESR=29 mm/hour, Hb=9.8 g/dL, WBC=13400/ μ L (PMN=80%, lymph=17%, mixed monocyte and eosinophil=3%); normal platelet count, LFT, RFT; Serological screening for Echinococcosis by enzyme-linked immunosorbent assay (ELIZA) was positive. Transthoracic (Fig. 4a) and transesophageal (Fig. 4b) echocardiographic examinations showed a large, well-defined, heterogeneous mass (2.5 x 2.5 cm) in the roof of the RA with attachment to the crista terminalis with a small stalk and no compressive effect on the IVC and SVC.

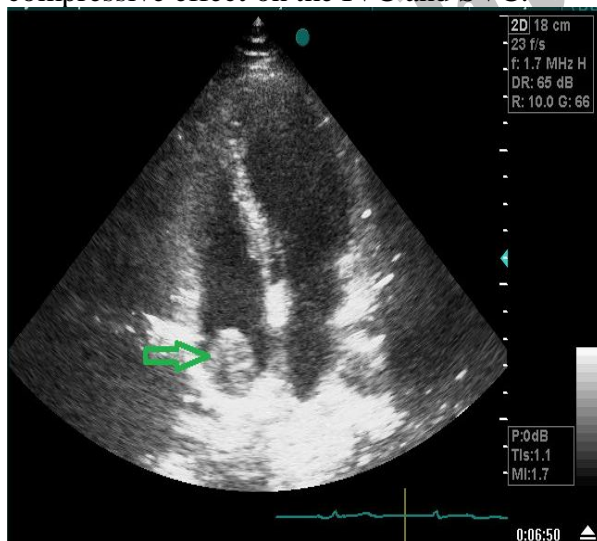


Fig. 4a: 2-dimensional transthoracic echocardiogram in apical 4-chamber view shows a large heterogeneous mass in roof of right atrium (green arrow)

In addition, there was no visible mass in the main PA and proximal PA branches.

Multi-Slice Spiral abdominal and pelvic CT scan with IV and oral contrast media were performed, and they were within normal limits.

The patient was scheduled for surgical mass resection on the seventh day of hospital admission. Surgery was performed successfully, and the first diagnosis of the surgeon was a hydatid cyst. Pathology examination approved the diagnosis of a hydatid cyst.

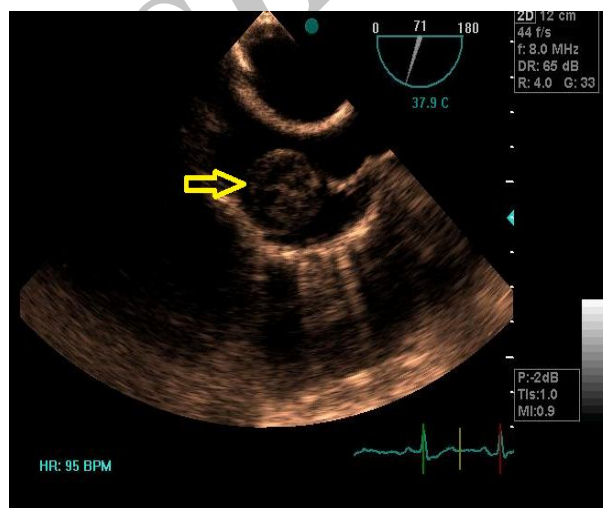


Fig. 4b: 2-dimensional transesophageal echocardiogram in midesophageal level (70 degree) shows a large heterogeneous mass in roof of right atrium without obstruction of superior or inferior vena cava (yellow arrow)

Discussion

The hydatid cyst is a parasitic disease caused commonly by the tapeworm *Echinococcus granulosus*.⁶ *Echinococcus* infestation occurs in humans when they accidentally eat *Echinococcus* eggs.⁶ Iran is an endemic area for hydatid cysts, and hydatid disease is, therefore, an important public health problem.

In **case 1**, we present an isolated cardiac hydatid cyst without involvement of the other organ systems. In the experience of Ruchan Akar et al., isolated cardiac involvement was also reported in 61% of their patients.⁷ The cause of primary, isolated, cardiac hydatid cyst is still unclear and needs further research. With respect to our country as an endemic area for hydatid disease, diagnosis of the cardiac hydatid cyst with typical cystic appearance in Echocardiography, CT, and MRI is easy. However, in rare cases with atypical and solid appearance, it can be difficult to distinguish hydatid disease from cardiac tumors. We herein present an isolated semisolid hydatid cyst probably because of cyst infection, which is a secondary complication of hydatid disease, imitating a cardiac tumor.

The right ventricle's hydatid cysts are ruptured more often than the left ventricle's hydatid cysts because of the subendocardial location.⁶ We chose the surgical approach to make correct diagnosis, effect best treatment, and prevent complications.

In agreement with previous reports⁸, a negative serology test cannot rule out the diagnosis of the hydatid cyst.

In **case 2**, the occurrence of the hydatid cyst in the right atrium has been reported rarely. The hydatid cyst is located in the right atrium about 9.7% of the times.⁹ There is a coincidence between lungs involvement and the RA hydatid cyst, as was the case in our experience. Consequently, so we believe that the contagious way is a route of the RA infection after lung involvement by the hydatid cyst.

Conclusion

These cases presented here highlight the importance of the cystic nature of the cardiac hydatid cyst in reaching diagnosis via echocardiography, CT, and MRI. The cardiac hydatid cyst with a solid appearance can

confuse us and imitate heart tumors in all the mentioned modalities.

As right-sided hydatid cysts have a tendency to expand intracavitary and subendocardially because of rupture, they are more frequently seen in these cysts. As a result, right hydatid cysts should be treated by early surgical excision to prevent the risk of rupture, anaphylaxis, sudden death, and also pulmonary embolus.

References

1. Ufuk Ozergin, Kadir Durgut, Niyazi Gormus. Infected Myocardial Hydatid Cyst Imitating Pericardial Cyst. *Asian Cardiovas Thorac Ann* 2001; 9:320-321.
2. Perez-Gomez F, Duran H, Tamamer S, Perrote JL, Blanes A. Cardiac Echinococcosis: clinical pictures and complications. *Br Heart J* 1973; 35:1326-1331.
3. Rasheed A Saad, Khalid MA Amer, Marcello Migliore, Tarek Azis. Right Hydatid cyst of the Heart. *Asian Cardiovas Thorac Ann* 2003; 11(2):160-162
4. Kaplan M, Demirtas M, Cimen S, Ozler A. Cardiac Hydatid Cyst with Intracavitary Expansion. *Ann Thorac Surg* 2001; 71:1587-905.
5. Memduh Dursun, Ege Terzibasoglu, Ravza Yilmaz et al. Cardiac Hydatid Disease: CT and MRI Findings. *AJR* 2008; 190:226-232.
6. Habib Thameur, Sami Abdelmoula, Slim Chenik et al. Cardiopericardial Hydatid Cyst. *World Journal of Surgery* 2001; 25: 58-67
7. Ruchan Akar, Sadik Eryilmaz, Neyyir Tuncay Eren. Surgery for Cardiac Hydatid Disease: An Anatolian Experience. *Anadolu Kardiyol Derg* 2003; 3:238-244
8. A Sadeghpour, B Nemati, S Arefi et al. 11 years experience with cardiac Hydatid cyst operation at Rajaee Heart Center. *Iranian Heart Journal* 2004; 5(4):40-44.

9. Deuyan Mansuroglu, Suat Nail omeroglu, Ramazan Akdemir. Right atrial hydatid cyst prolapsing into the tricuspid valve. Tex Heart Inst J. 2004; 31(4):452-453

Archive of SID